

---

# **CASE RECORD**

**DR.FATIMA HASAN AHAMED MARIKE**

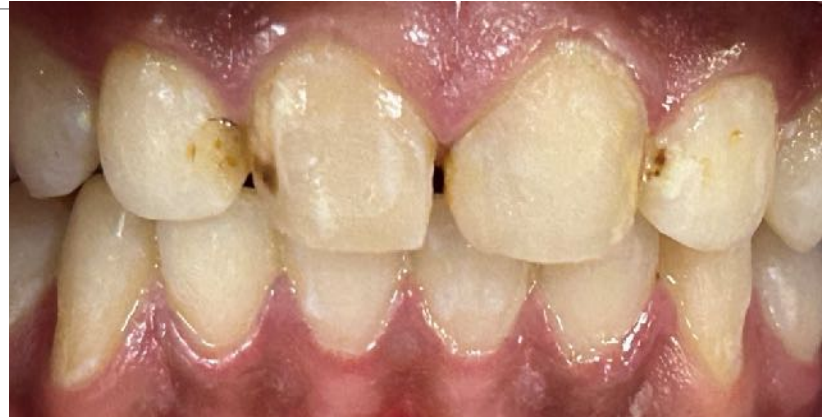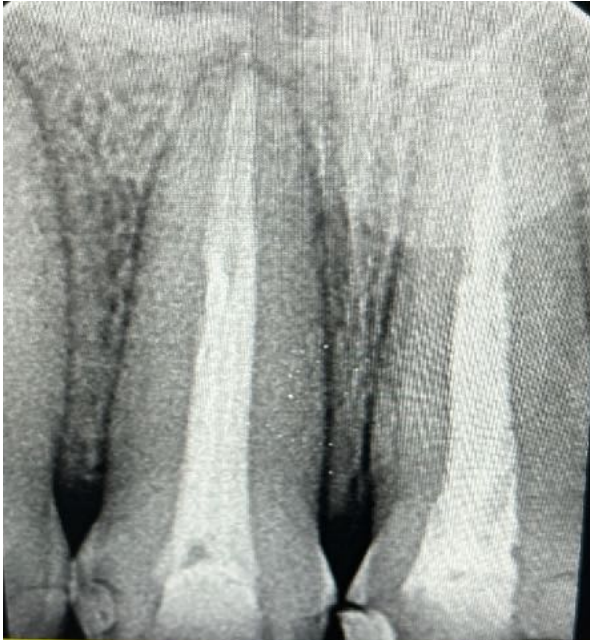# CASE 1

---

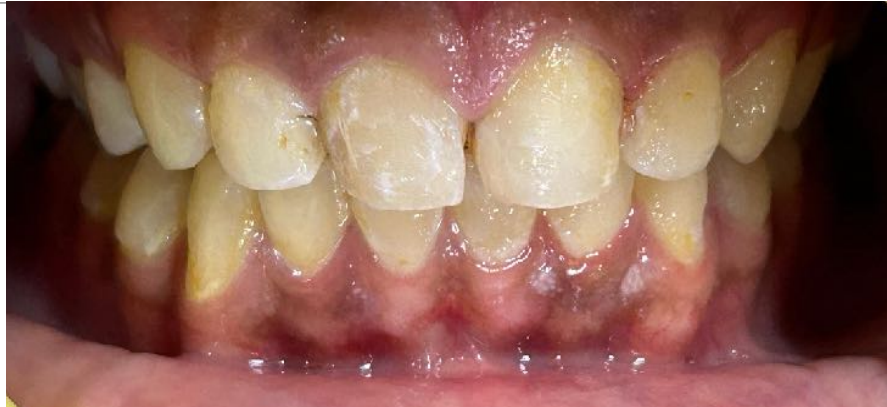## DIRECT COMPOSITE VENEER

- COMPLAINS OF-DISCOLORATION IN THE UPPER FRONT TOOTH REGION
- GENDER-MALE
- AGE-22
- TOOTH NUMBER-11,12,21,22

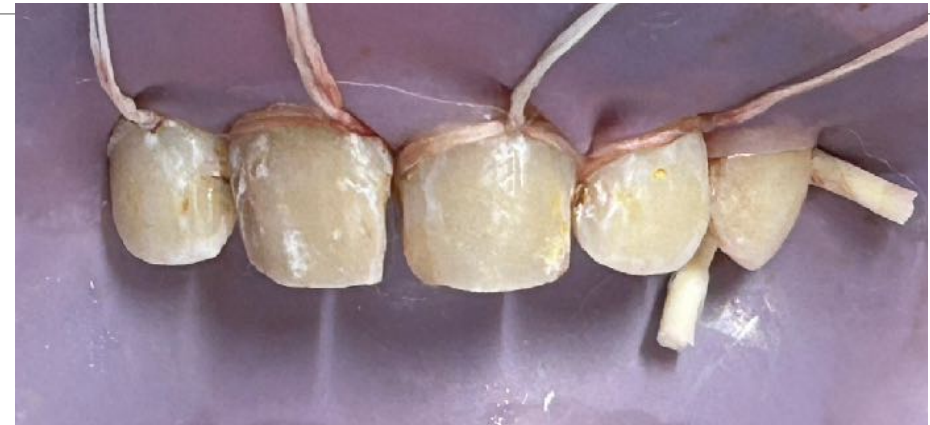Pre-operative radiograph



Pre-operative photographs with class III caries wrt 11, 12 ,21 ,22 with midline diastema and labial discoloration

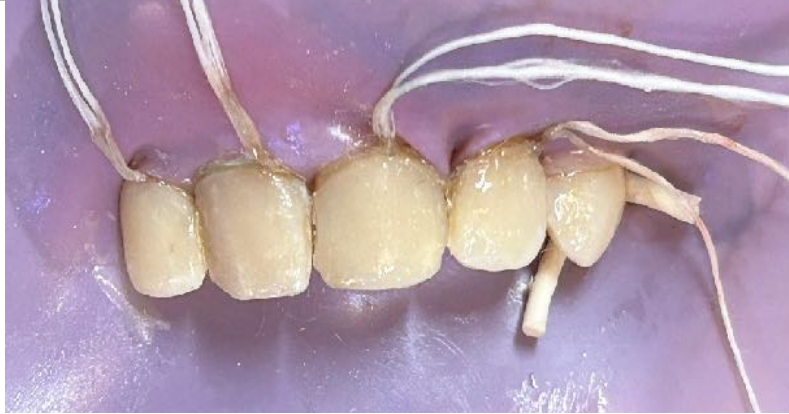

Scaling done and caries removed  
Window preparation done on facial surface

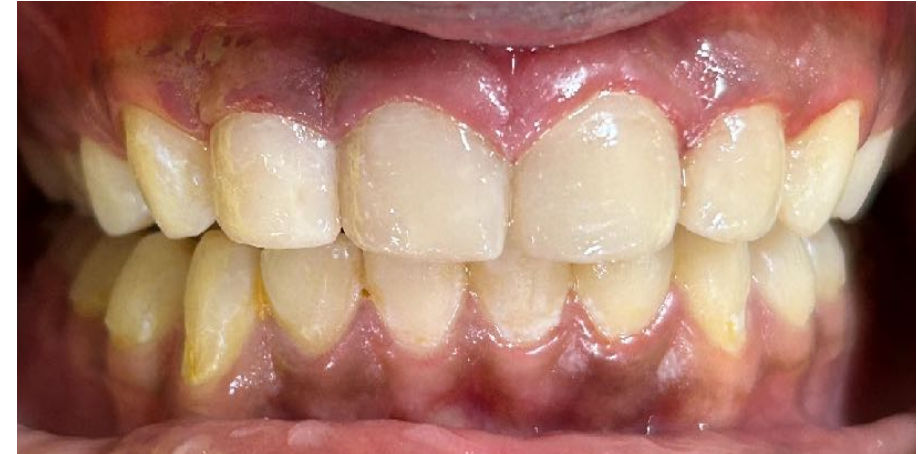

Rubber dam isolation done and floss tie placed

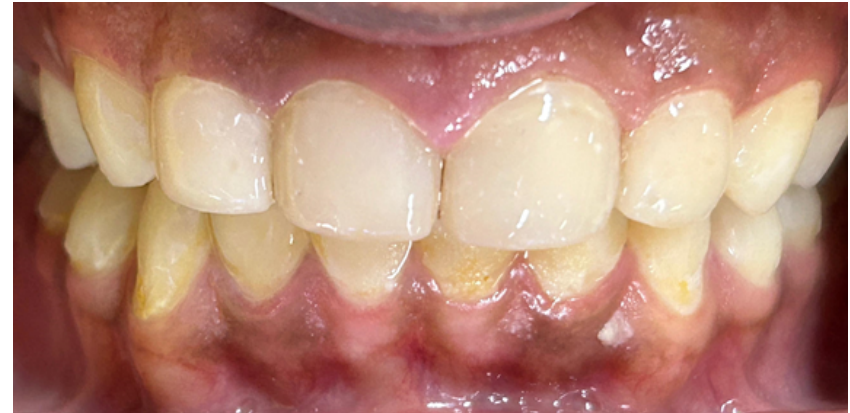
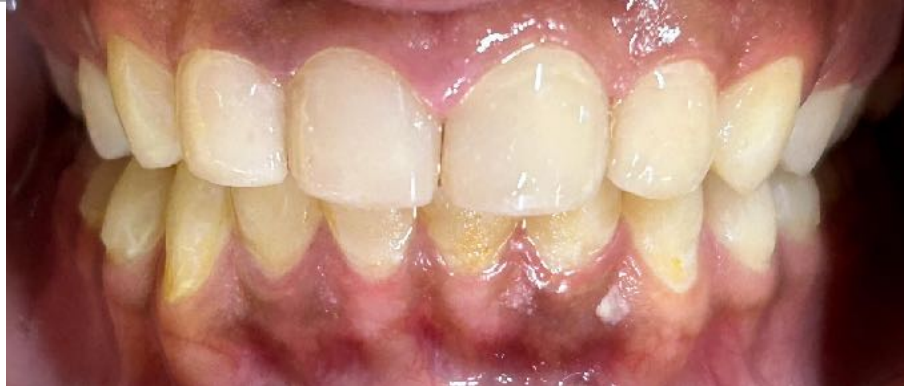


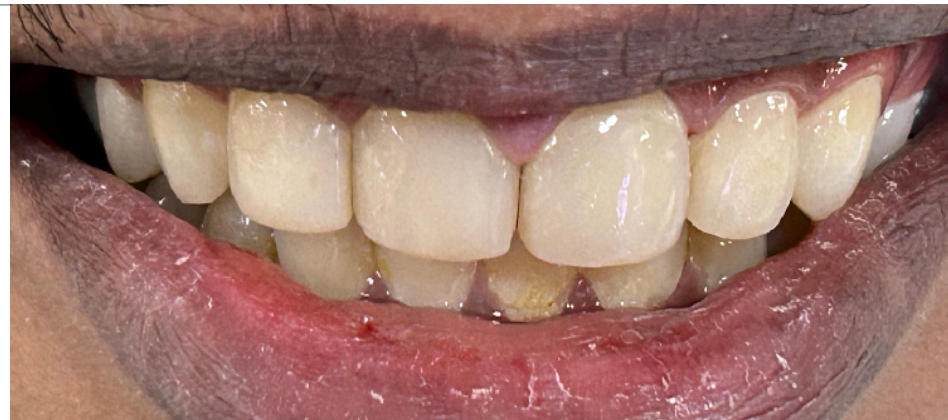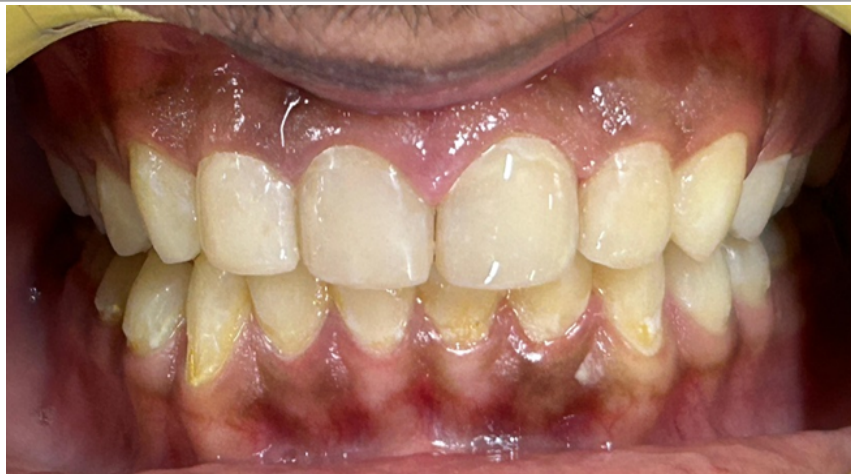After composite restoration.



After removal of rubber dam



Finishing done with white stone and finishing bur , polishing done with discs ,pumice and rubber cups.



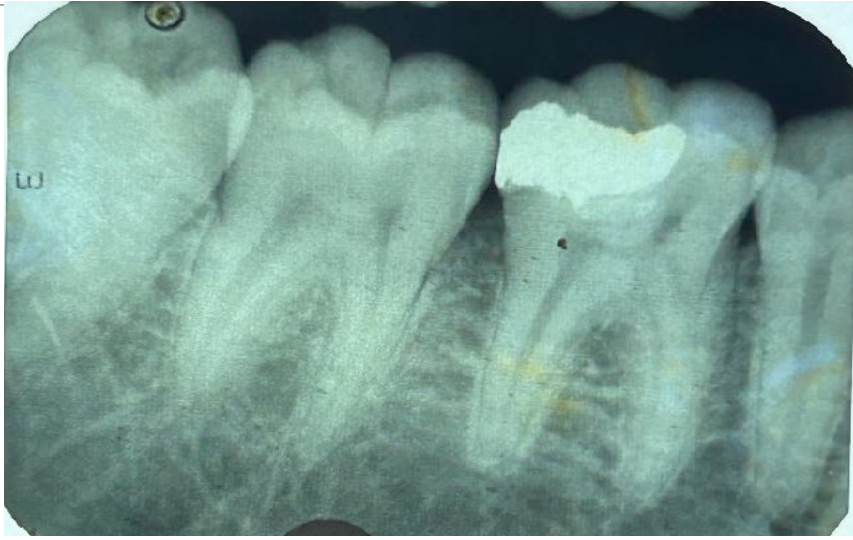
Post- operative photograph

## CASE 2

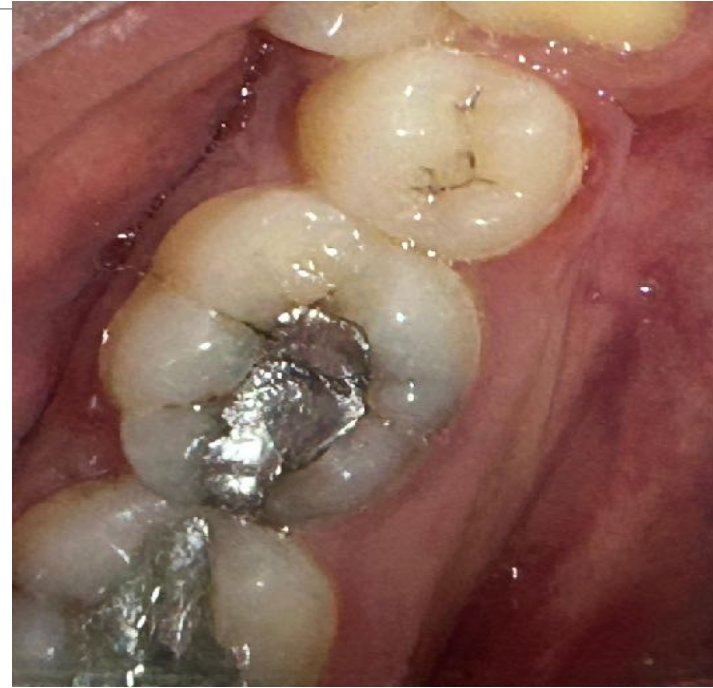---

# CLASS II COMPOSITE RESTORATION

- COMPLAINS OF- SENSITIVITY IN THE LOWER RIGHT BACK TOOTH REGION
- GENDER- MALE
- AGE- 29
- TOOTH NUMBER- 46

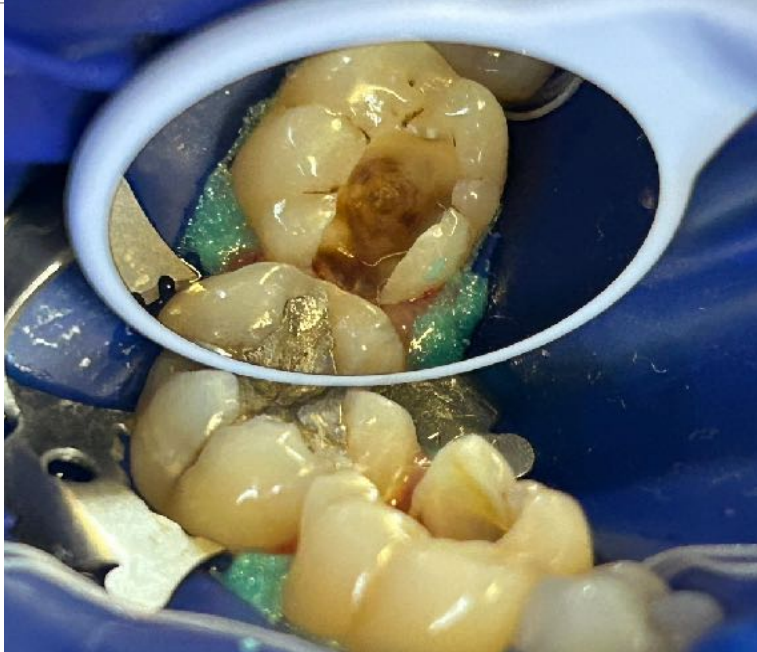

Pre-operative radiograph

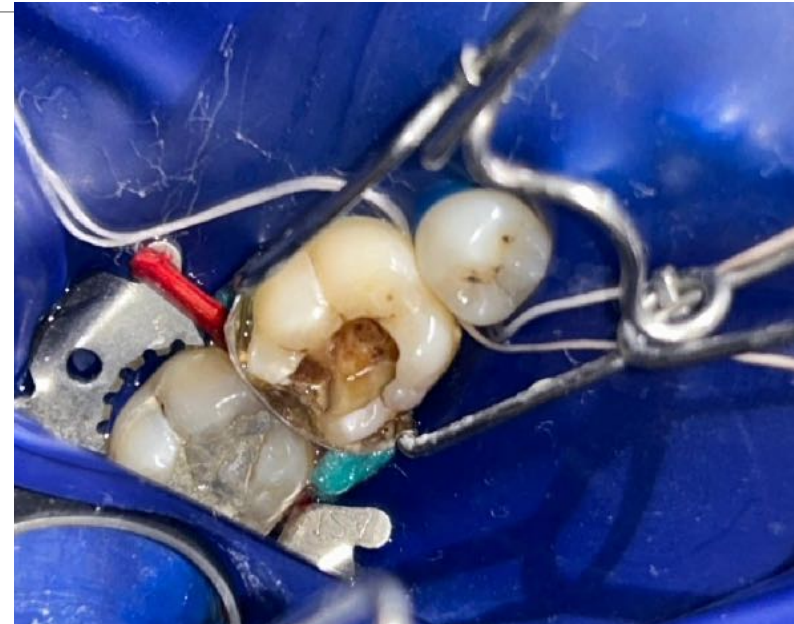

Intra-oral photograph showing amalgam restoration

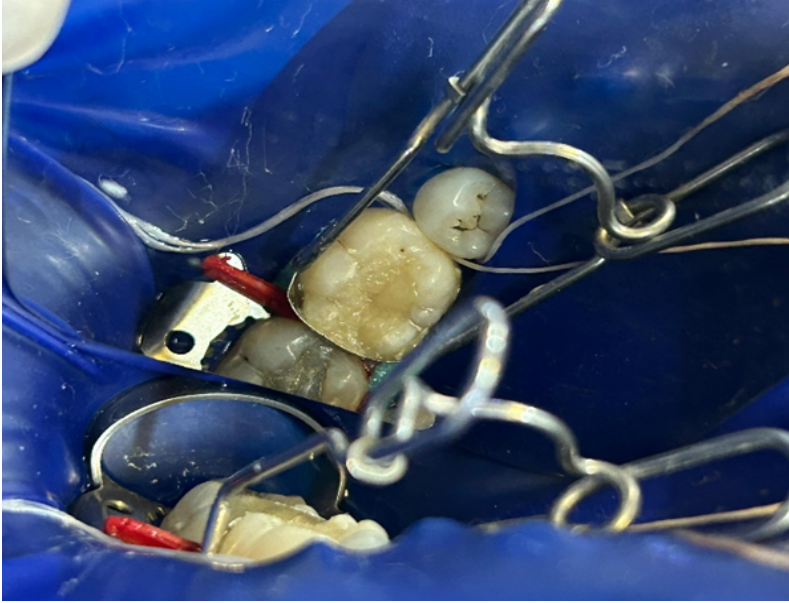



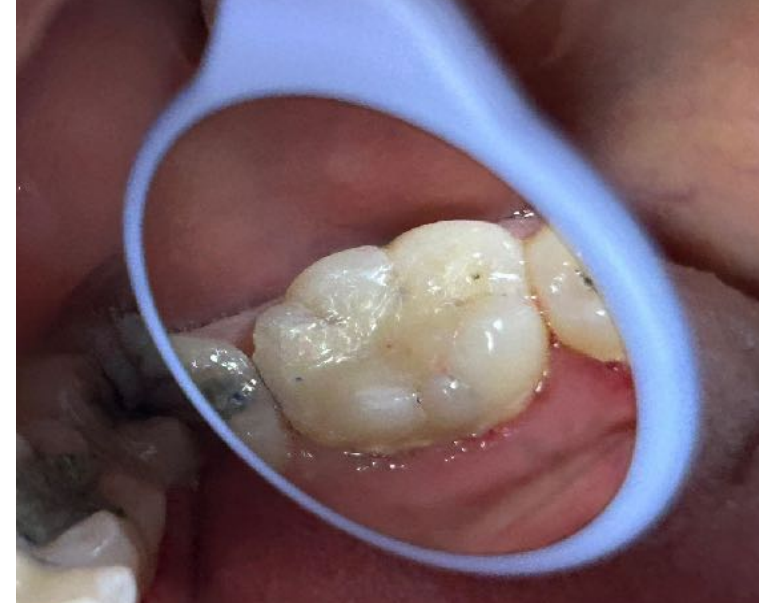Rubber dam isolation done, liquid dam placed  
Amalgam restoration and secondary caries  
removed



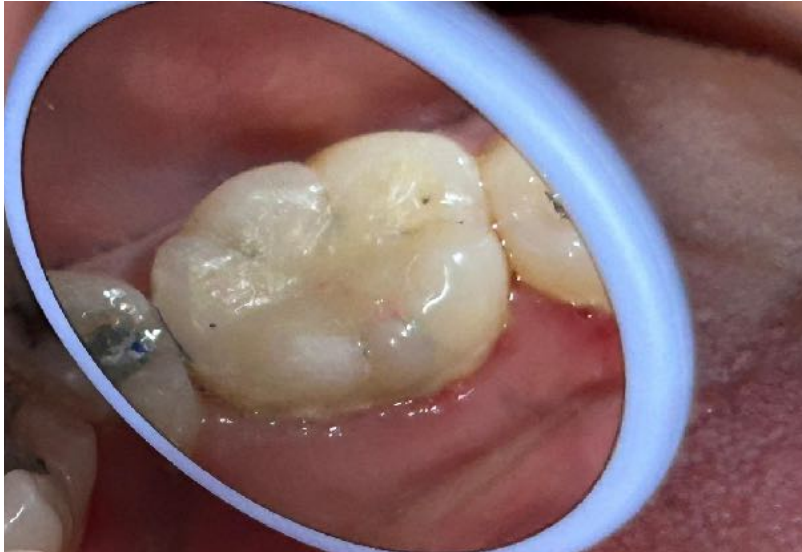Saddle matrix placed with  
wedge



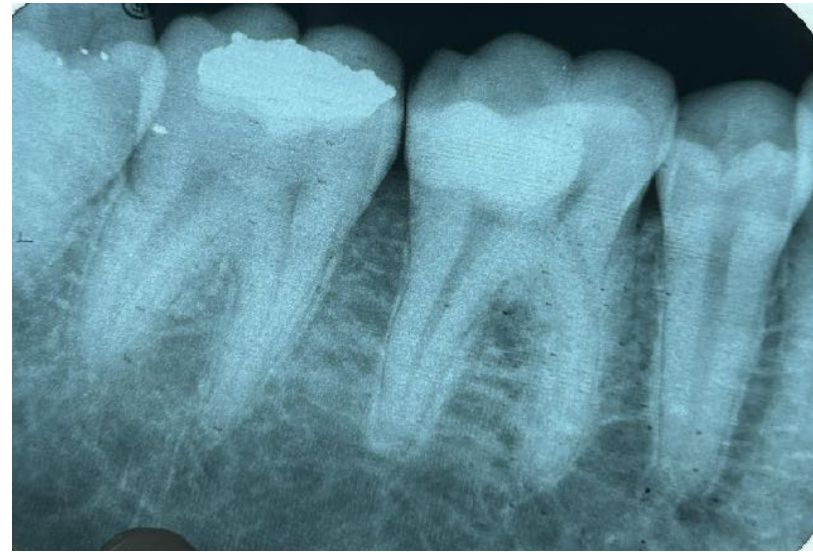Class II re-restoration with  
composite done



Rubber dam removed  
Finishing done by white stones  
and finishing bur



Polishing done with discs



Post operative radiograph

---

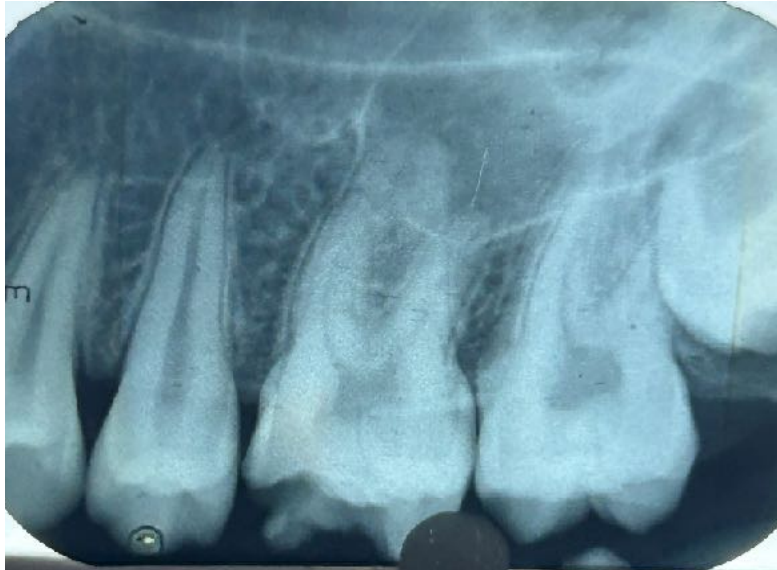

## CASE 3

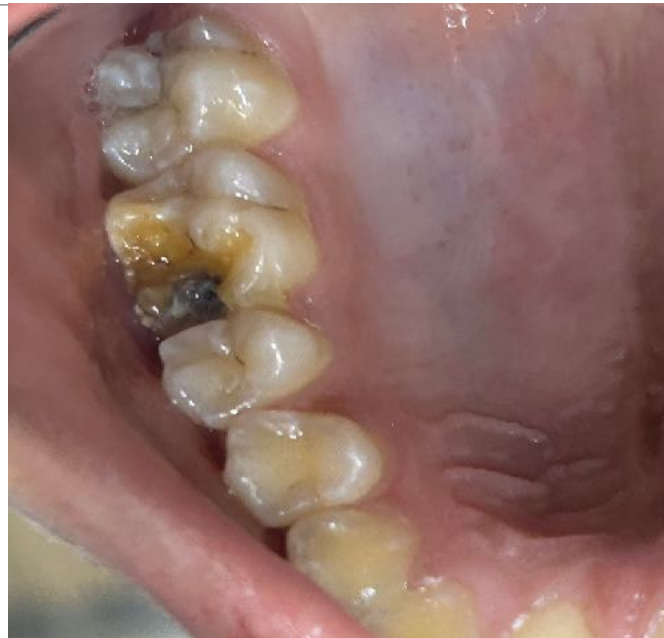---

# INDIRECT RESTORATION (INLAY)

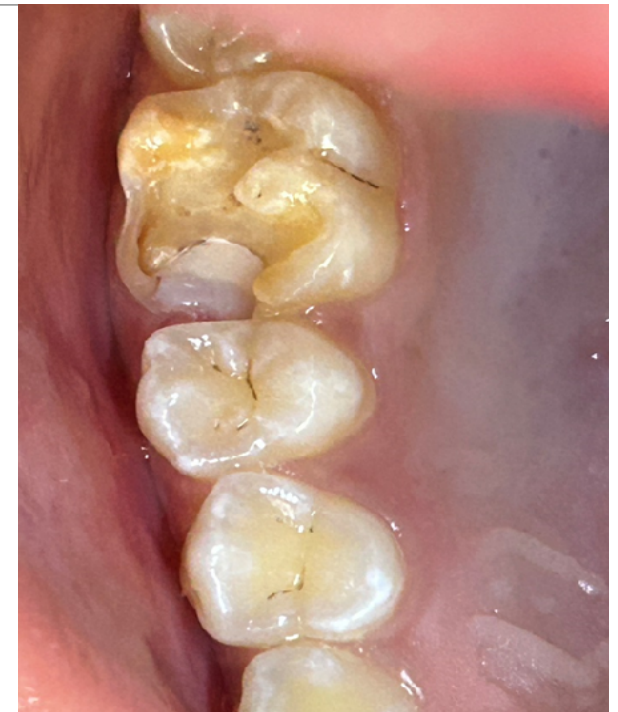- COMPLAINS OF- SENSITIVITY AND DECAY IN THE UPPER RIGHT BACK TOOTH REGION
- GENDER- FEMALE
- AGE- 19
- TOOTH NUMBER- 16



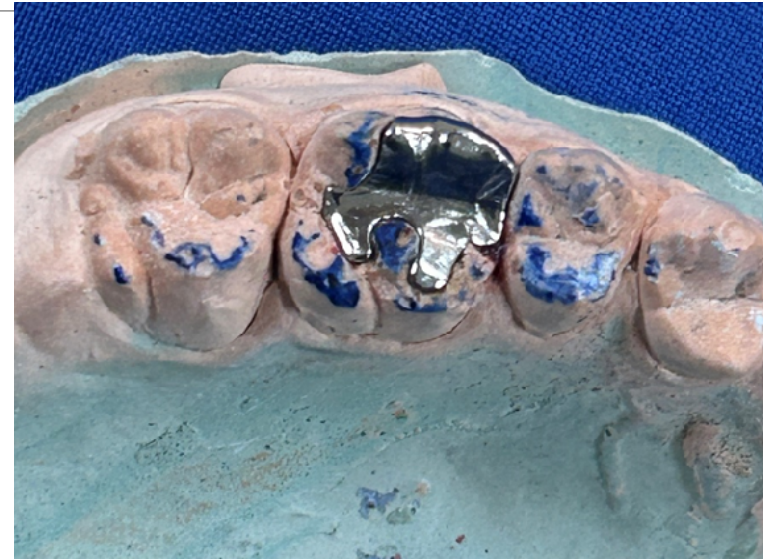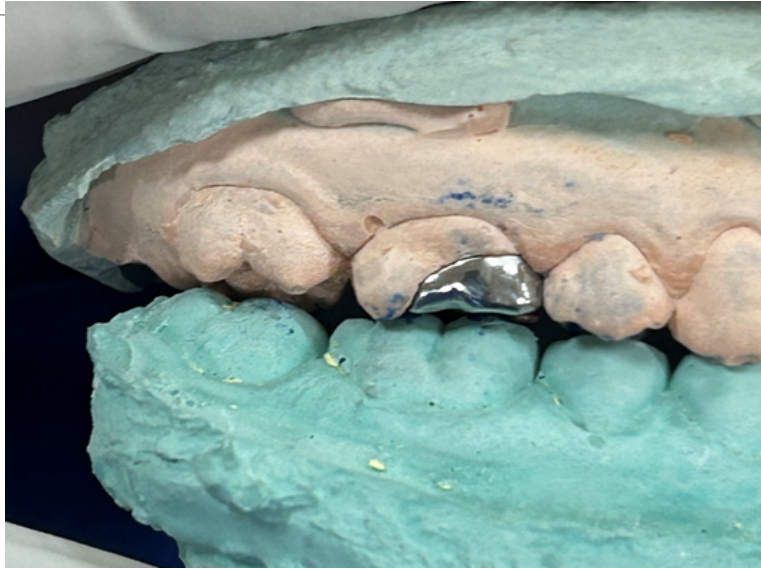Pre-operative radiograph



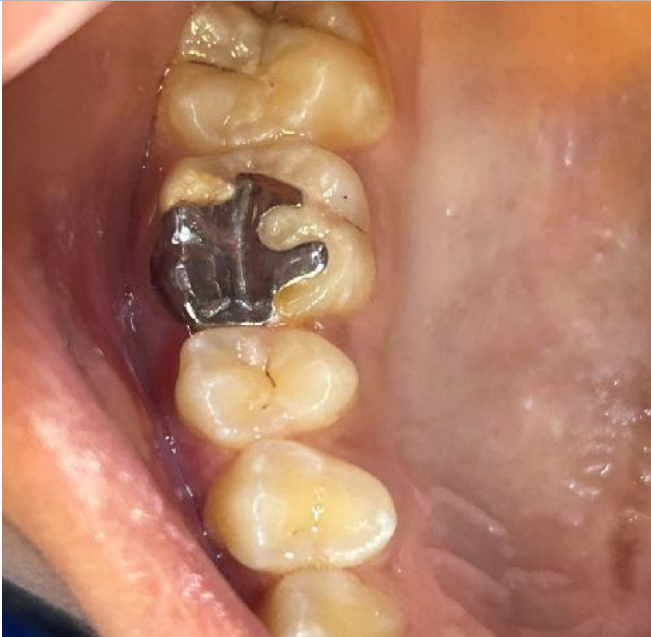Intra-oral photograph  
showing wide class II  
caries wrt 16



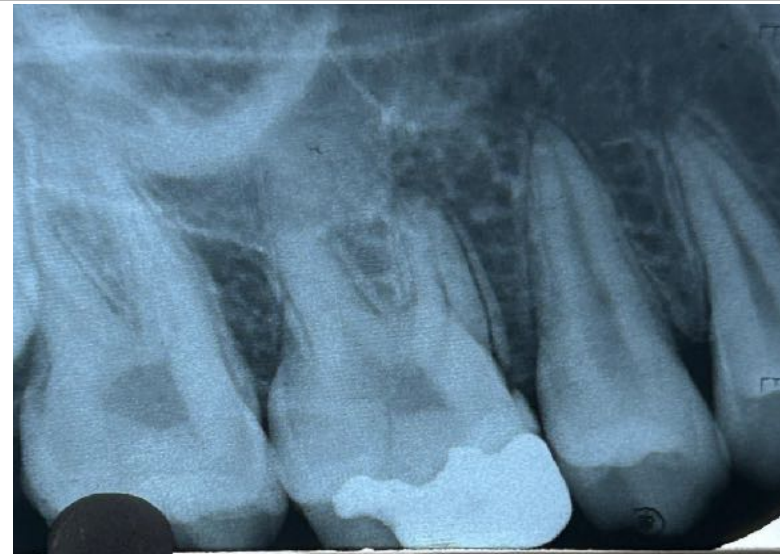Inlay preparation done



Metal inlay on diagnostic cast



Metal inlay cementation done



Post-operative radiograph

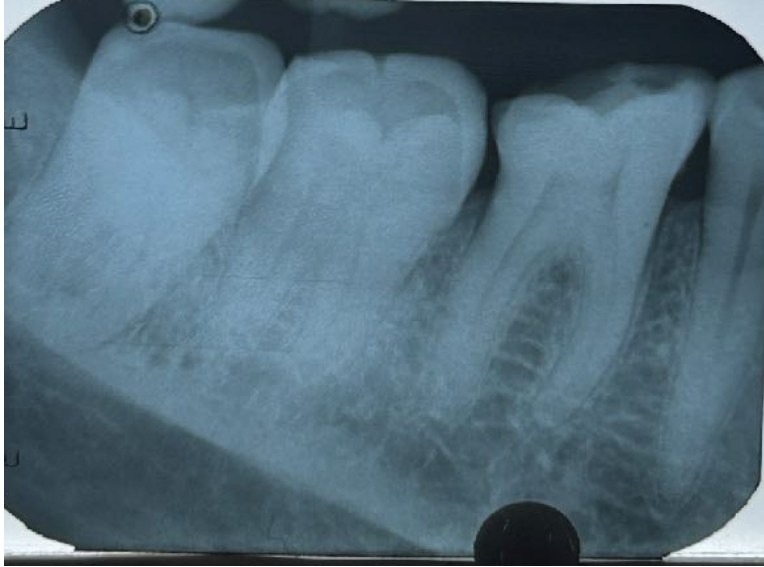## CASE 4

---

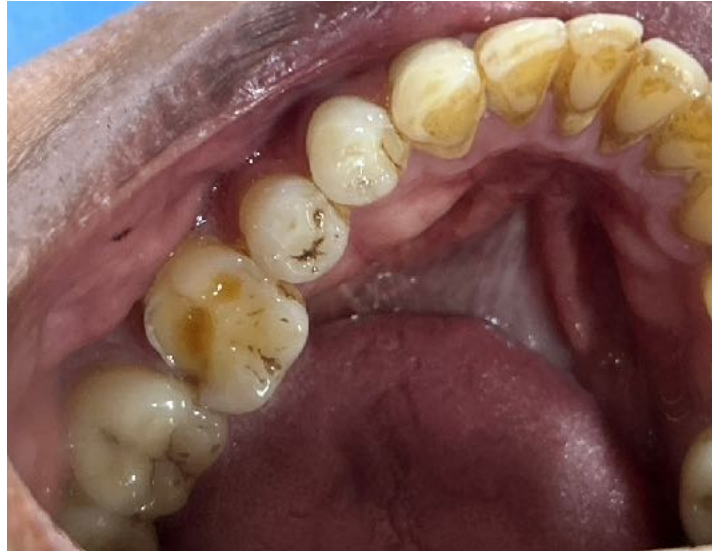# INDIRECT RESTORATION (ONLAY)

- COMPLAINS OF –FRACTURED TOOTH AND SENSITIVITY IN THE LOWER RIGHT BACK TOOTH REGION
- GENDER-MALE
- AGE-56
- TOOTH NUMBER-46

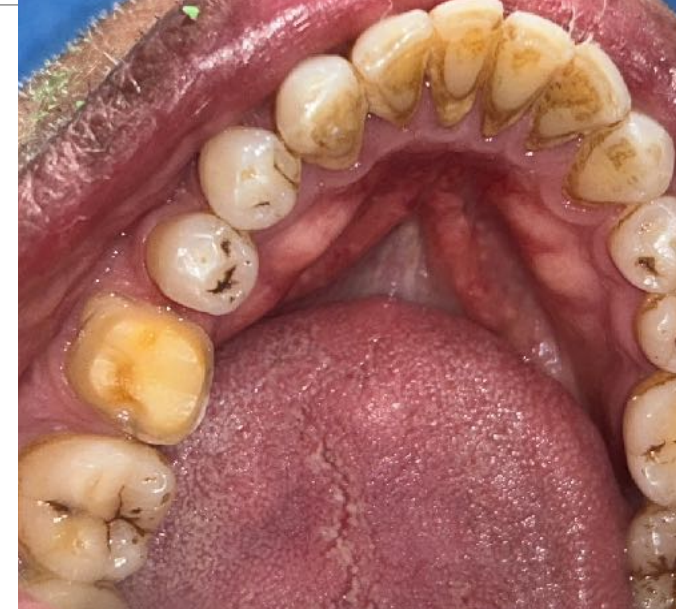



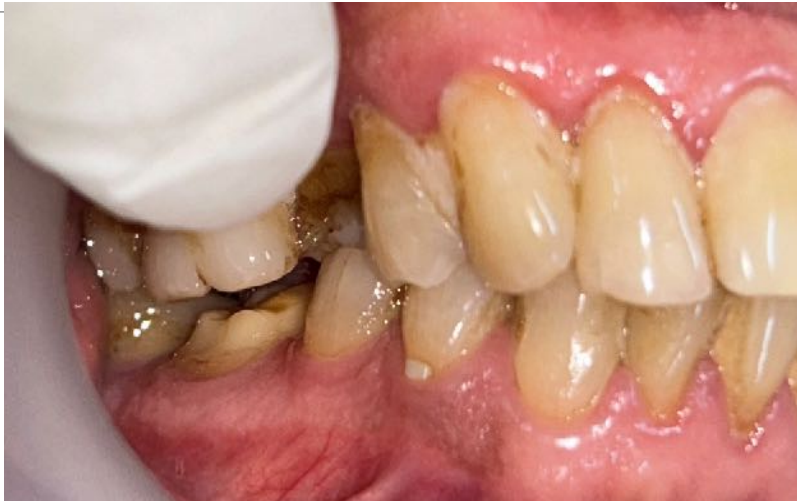Pre-operative radiograph



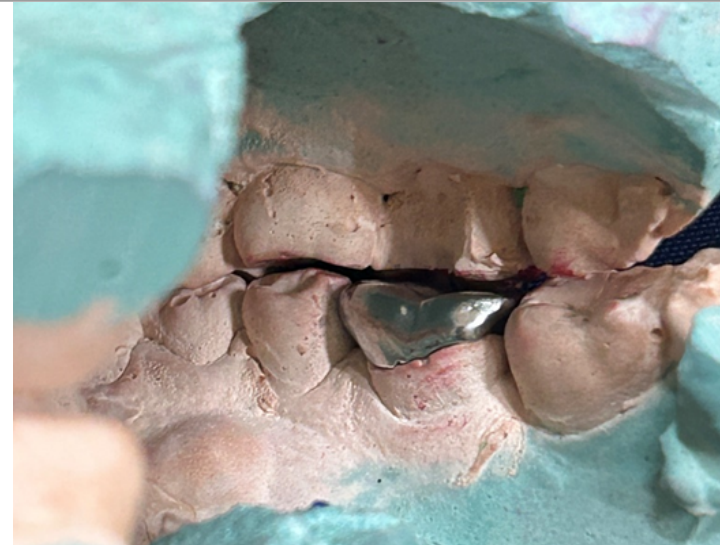Intra-oral photograph showing fractured buccal cusp



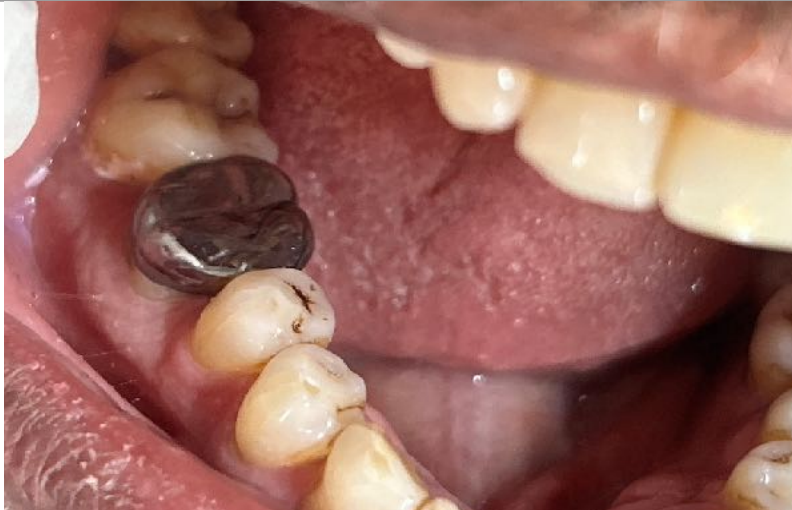Onlay preparation done wrt 46



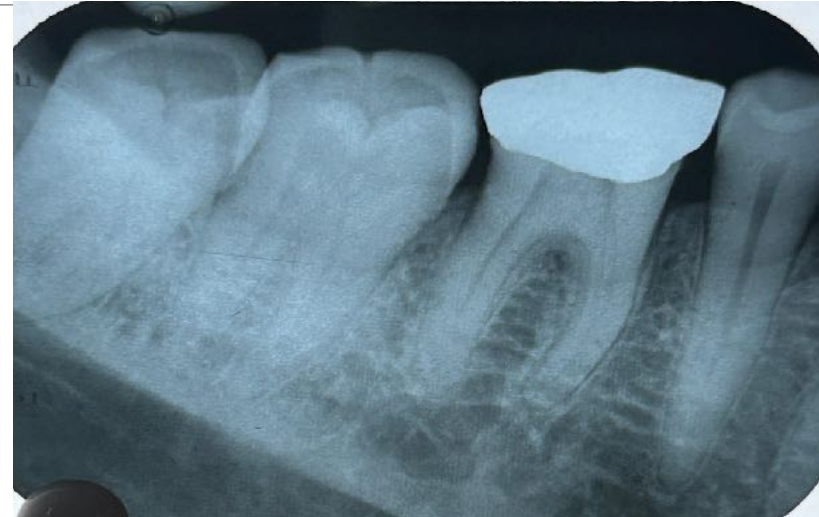Occlusal clearance



Metal onlay on diagnostic cast



Metal onlay cementation done wrt 46



Post-operative radiograph

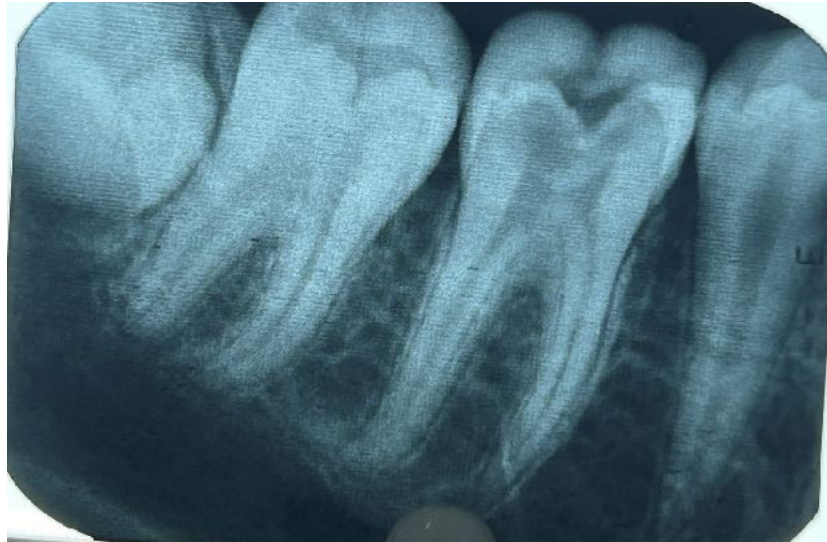


## CASE 5

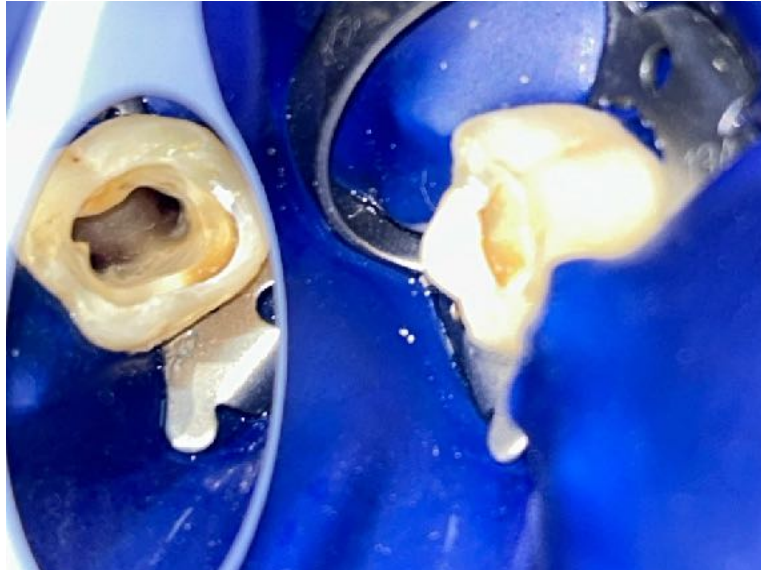---

# BROKEN FILE (ROOT CANAL TREATMENT)

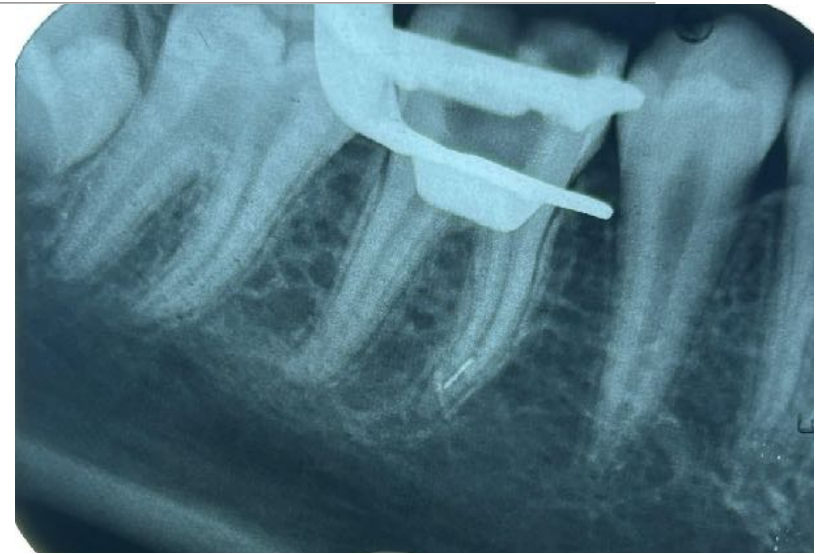- COMPLAINS OF-PAIN IN THE LOWER LEFT BACK TOOTH REGION
- GENDER-MALE
- AGE-14
- TOOTH NUMBER-36



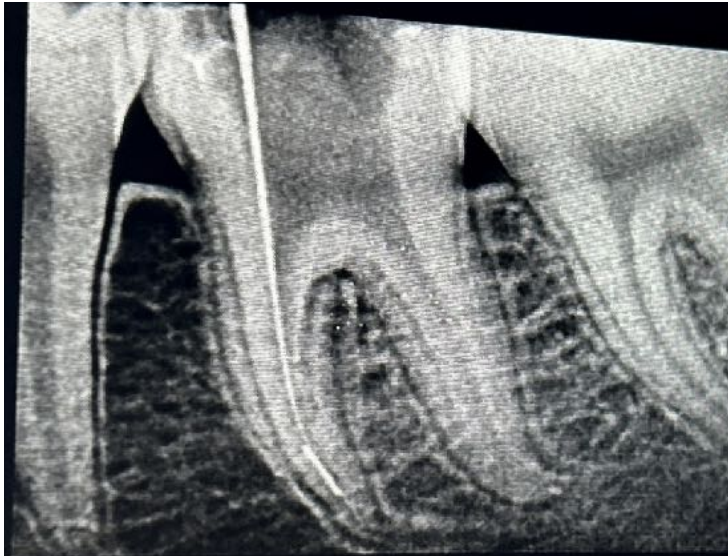
Pre-operative radiograph



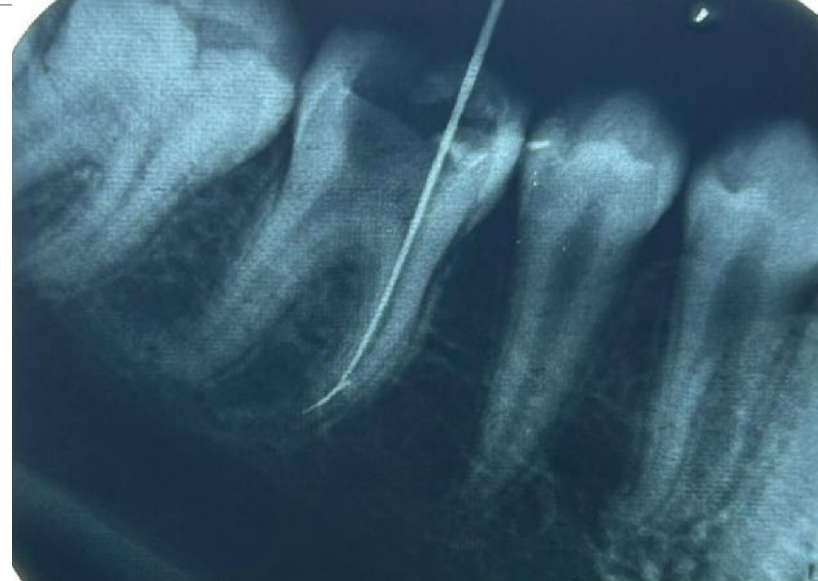Access opening done (MB, ML, D canals located) under rubber dam isolation



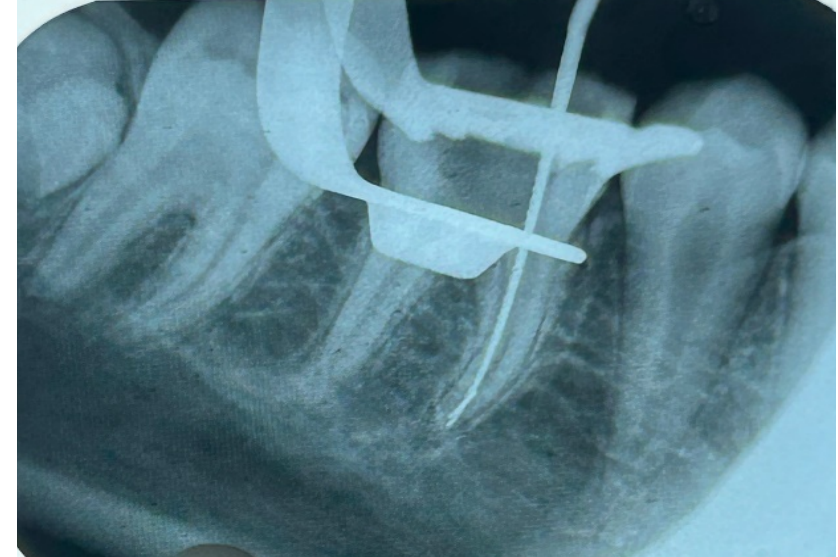
20 number file broke in mesiolingual canal while doing bmp(2mm above the WL)



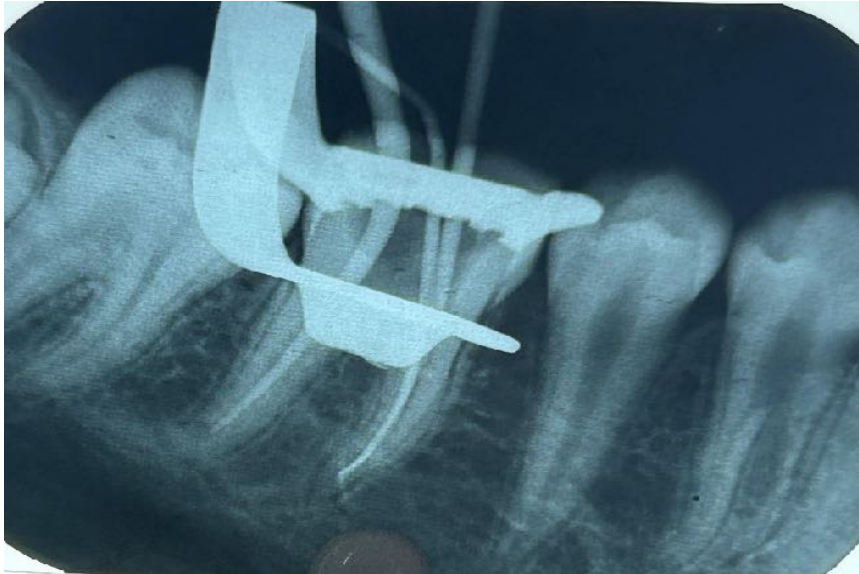
8 number file is bent at the tip (45degree) and negotiated



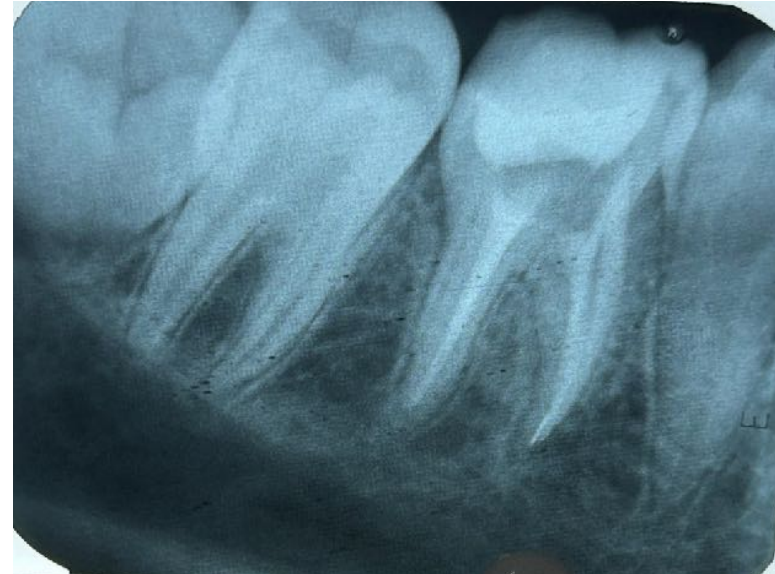15 number file negotiated in the same way



30 number file negotiated

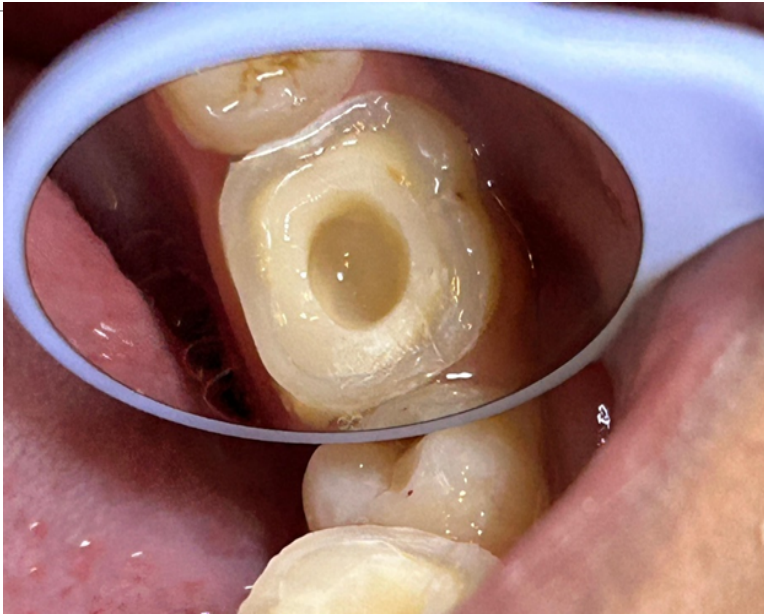


Master cone radiograph

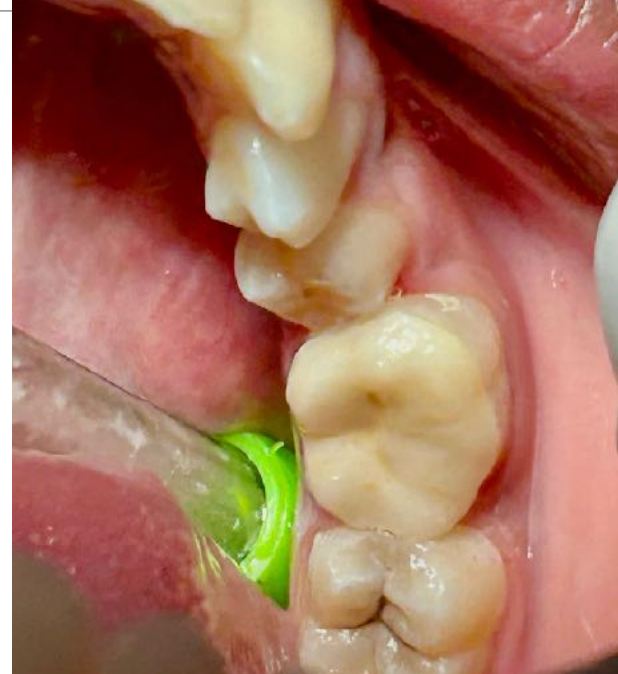

Obturation and post endo  
restoration done wrt 36





GIC liner placed  
Composite buildup done and  
preparation for endocrown  
done



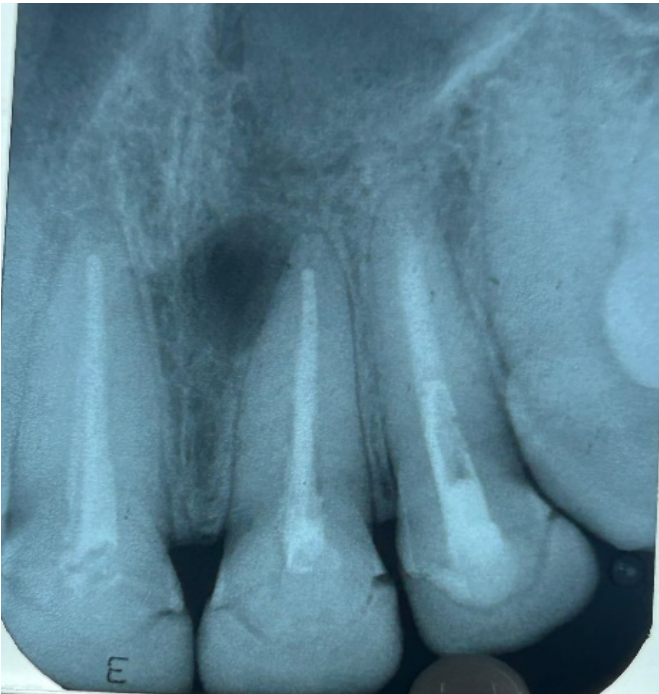Endocrown cementation  
done wrt 36

## CASE 6

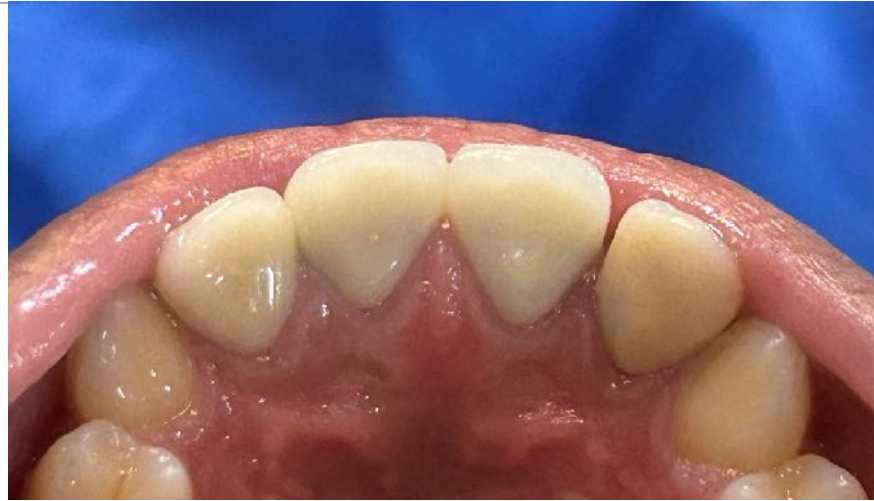---

# RE-ROOT CANAL (CYST)

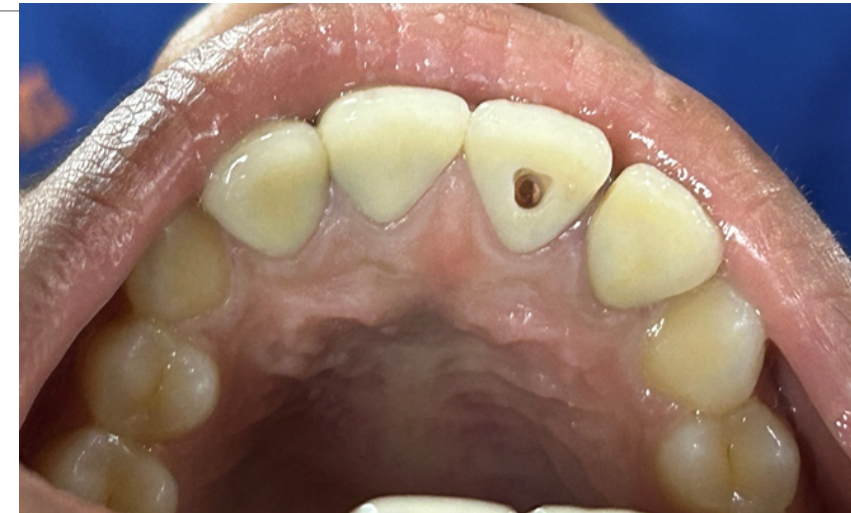- COMPLAINS OF –PAIN ON PALPATION ON THE LABIAL SURFACE OF MUCOSA
- GENDER-FEMALE
- AGE-19
- TOOTH NUMBER-11



Pre-operative radiograph

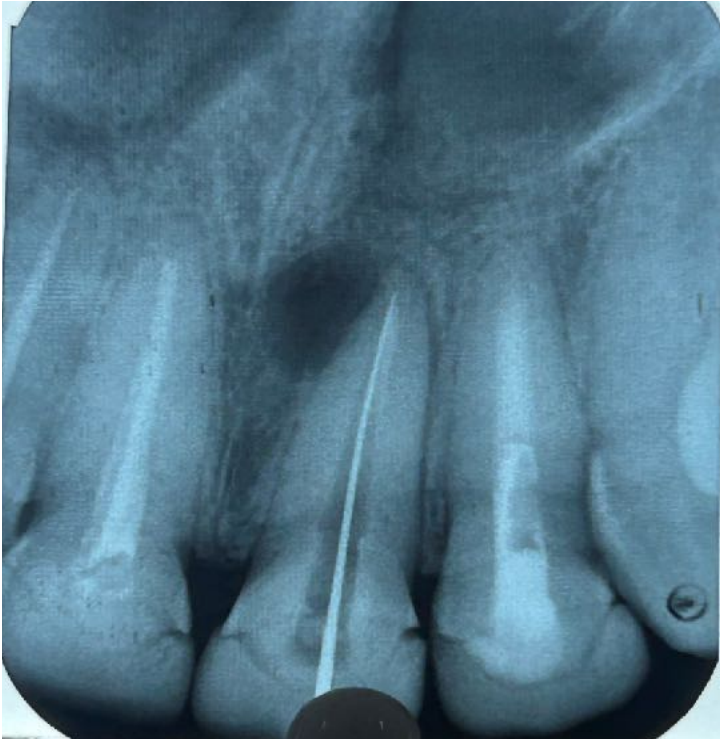

Intra-oral photograph showing Zirconia crown wrt 11,12,21,22

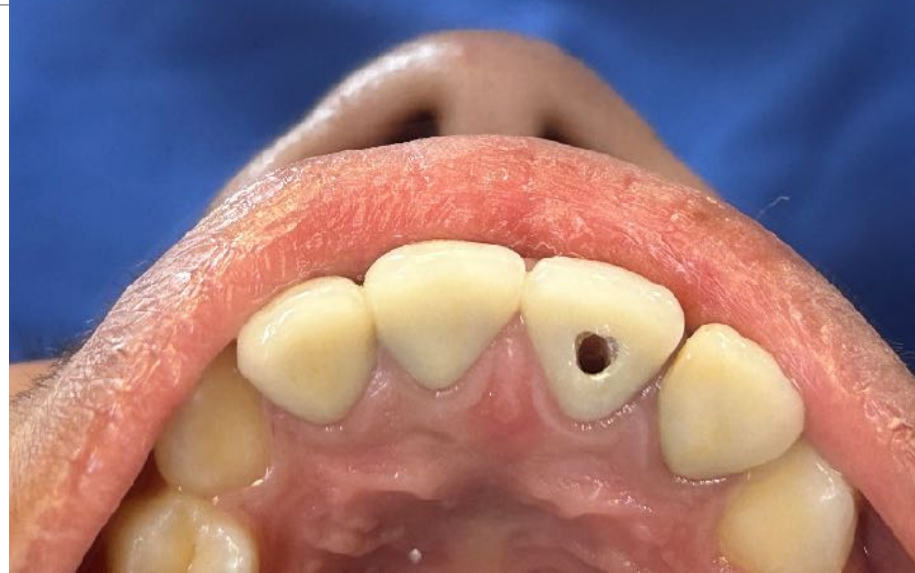

Access opening done wrt 11 through zirconia crown

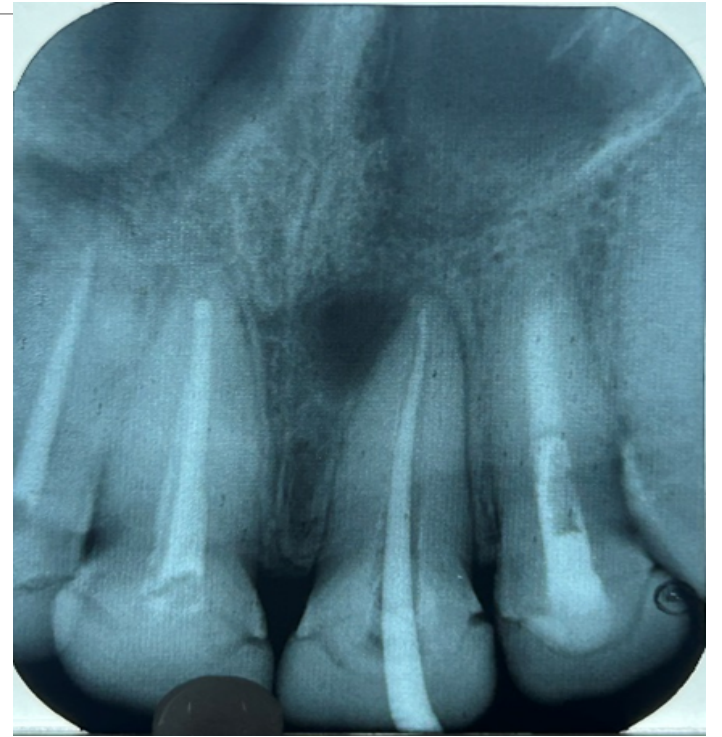



Working length radiograph  
taken

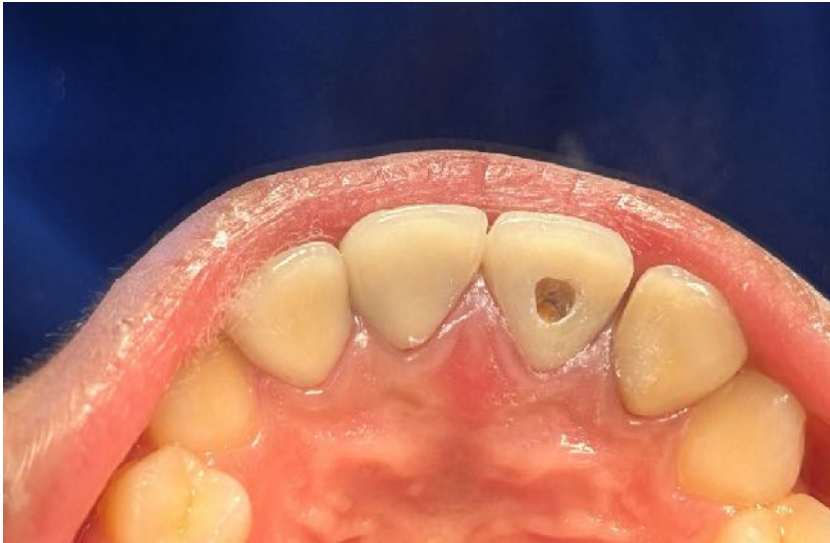

Intracanal medicament ( $\text{Ca(OH)}_2$ )  
placed  
Dressing changed every 3 days for 5  
times

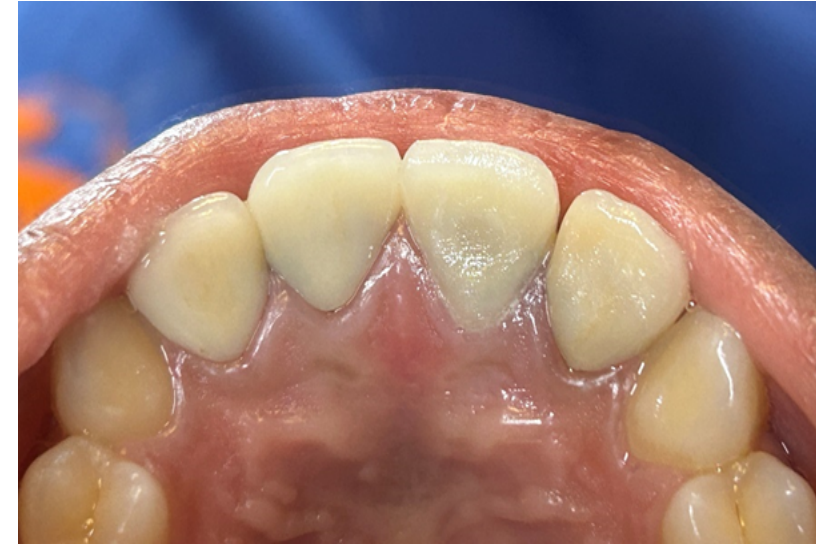
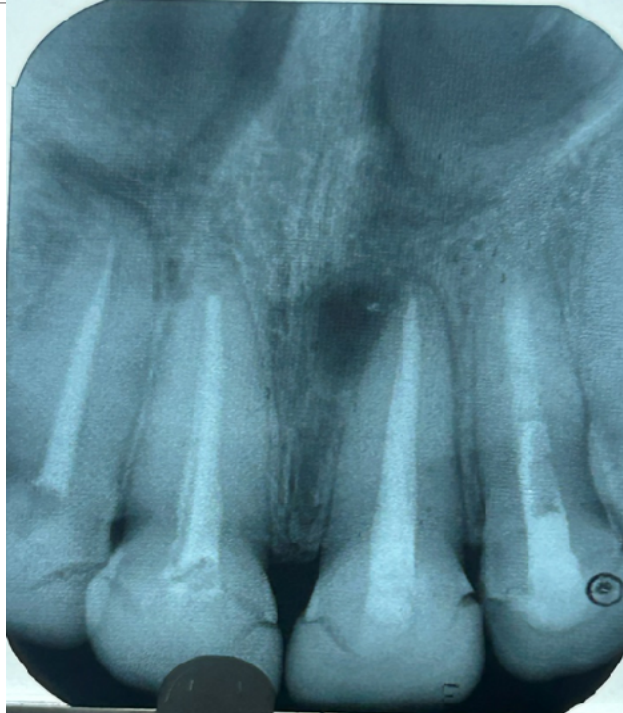
Master cone radiograph  
taken

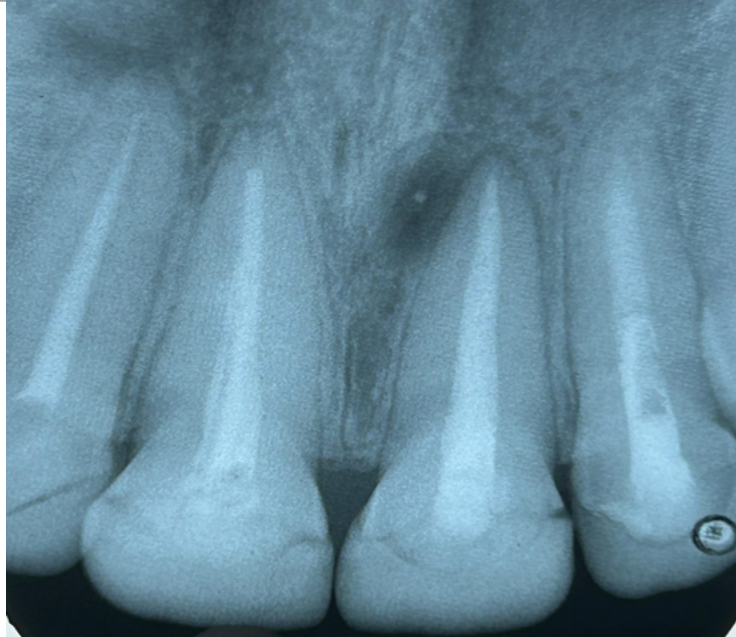



Obturation done wrt 11 and sealer has spread into lesion



Post endo-composite restoration done



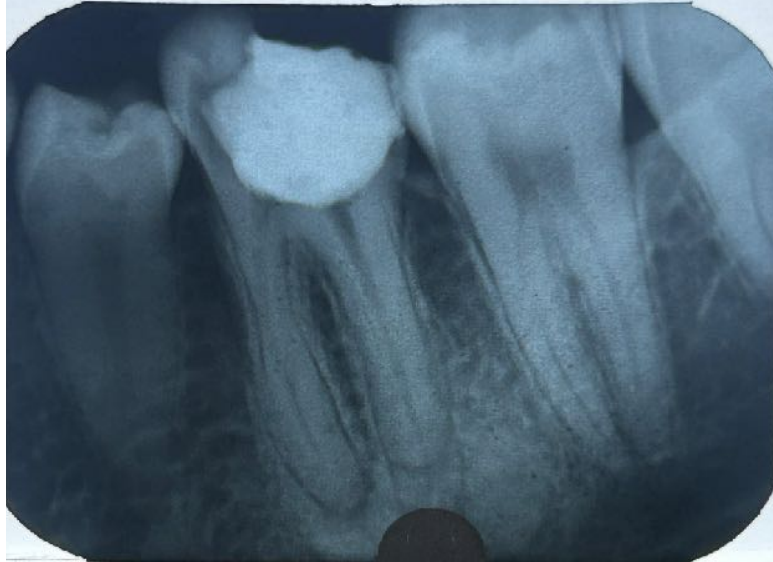After 1 month recall  
Lesion has reduced its size,  
Formation of bone rarefaction can be noticed

## CASE 7

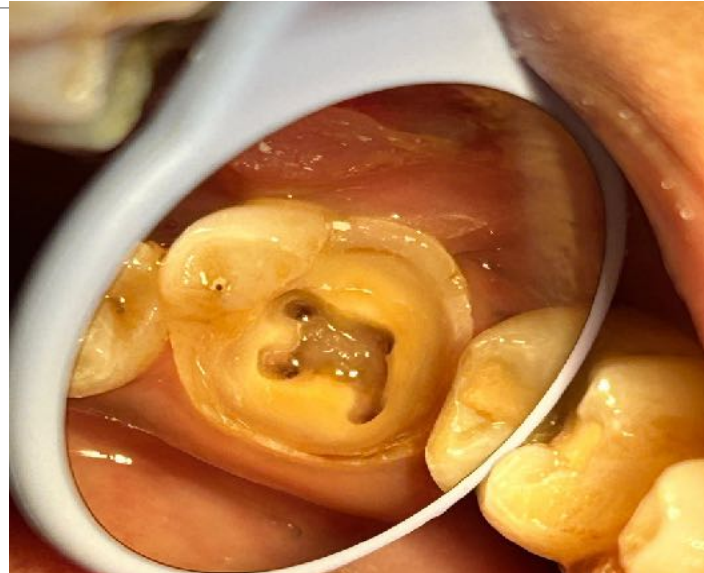---

# ROOT CANAL TREATMENT (RADIX ENTOMOLARIS WITH 2 POSTS)

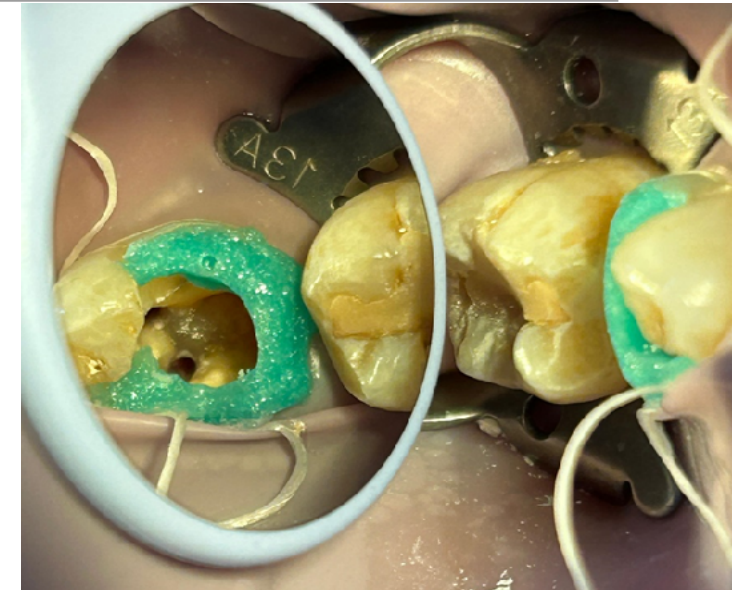
- COMPLAINS OF –PAIN IN THE LOWER LEFT BACK TOOTH REGION
- GENDER-FEMALE
- AGE-21
- TOOTH NUMBER-36



Pre-operative radiograph

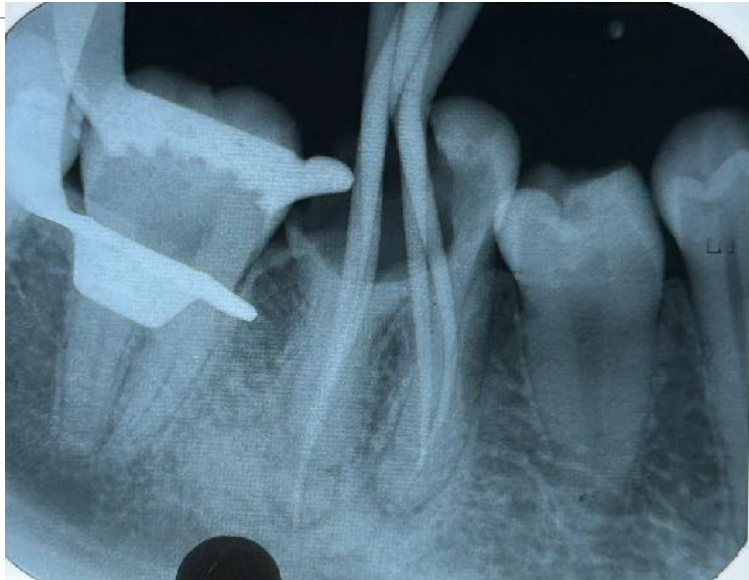

Access opening done-MB, ML,DB, DL  
canals located  
Distobuccal is buccally placed(radix)

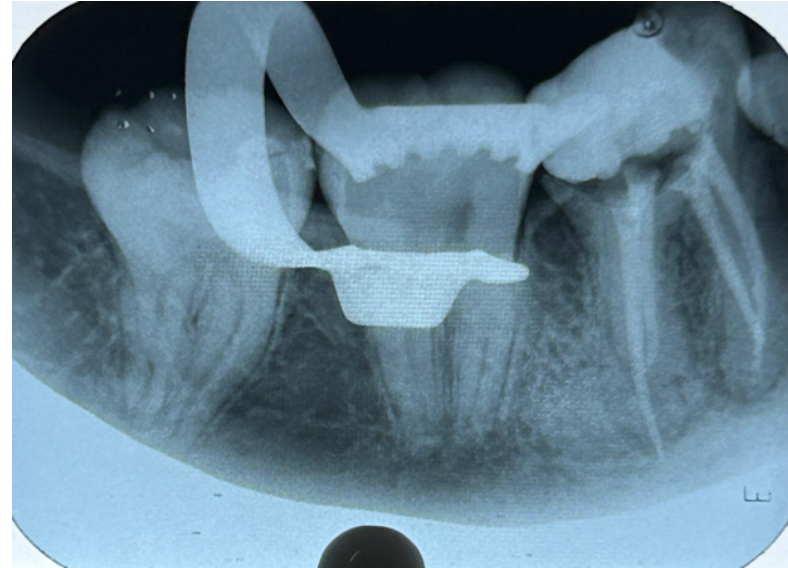


Rubber dam isolation and  
liquid dam placed.

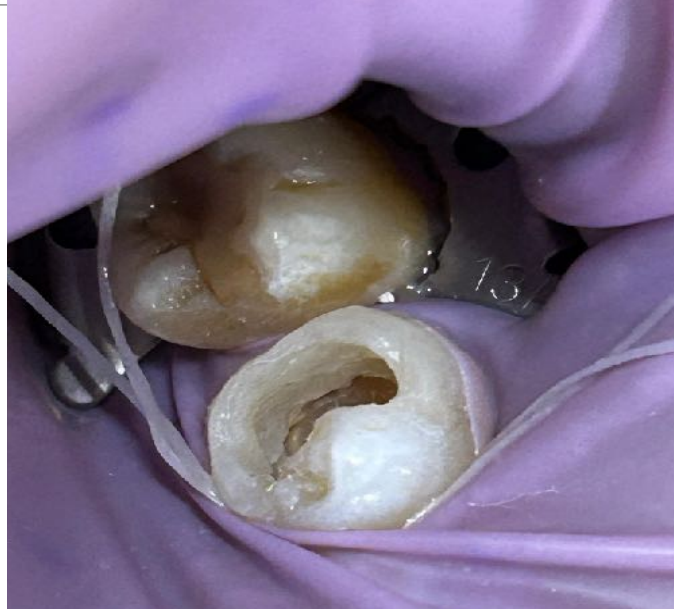



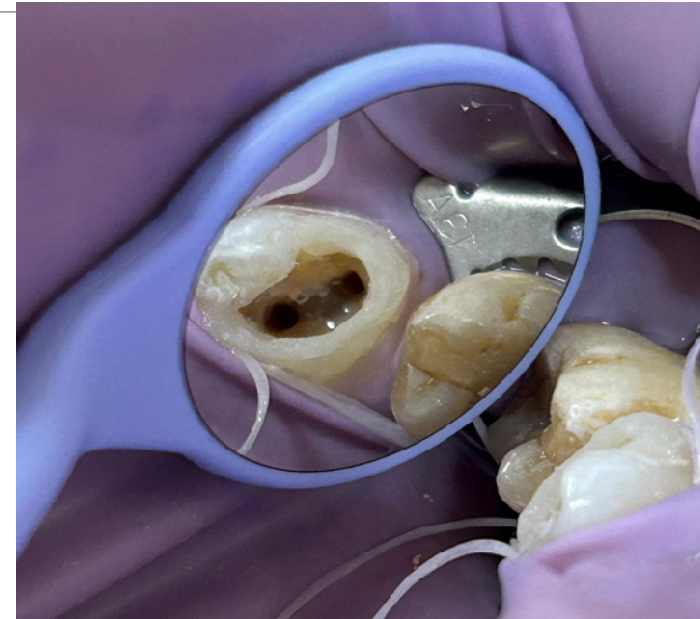
Mastercone radiograph



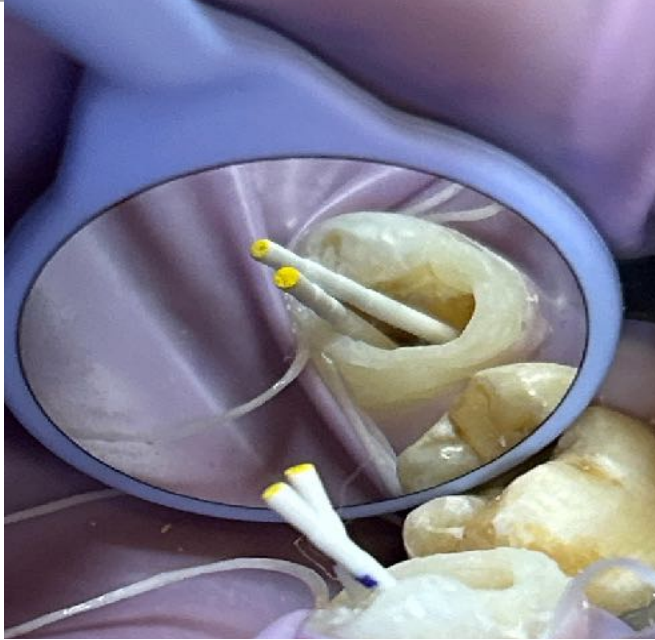
Obturation done wrt 36



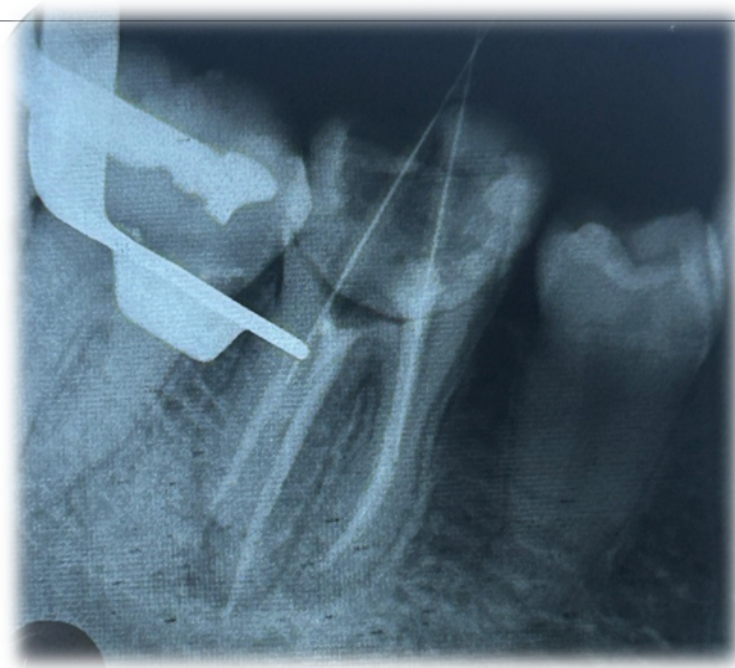
Composite build-up done under rubber dam



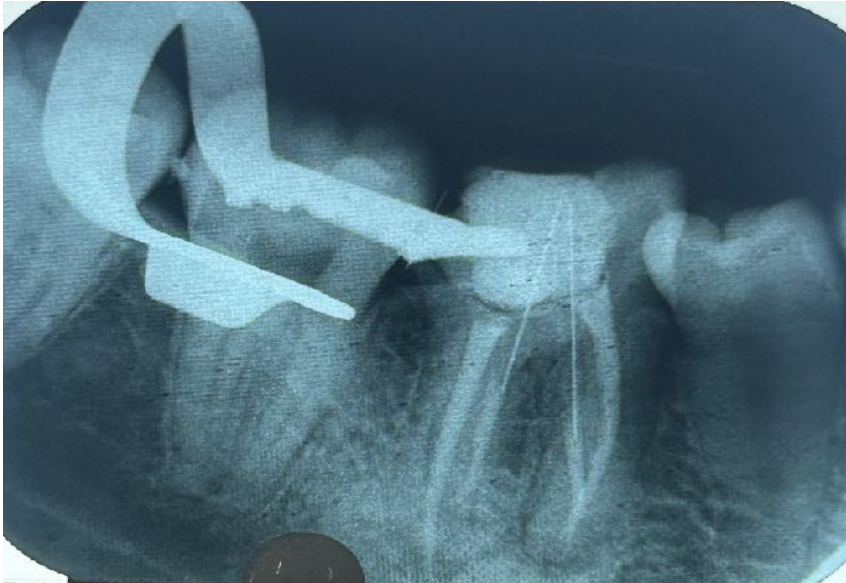2 post space prepared DB and ML



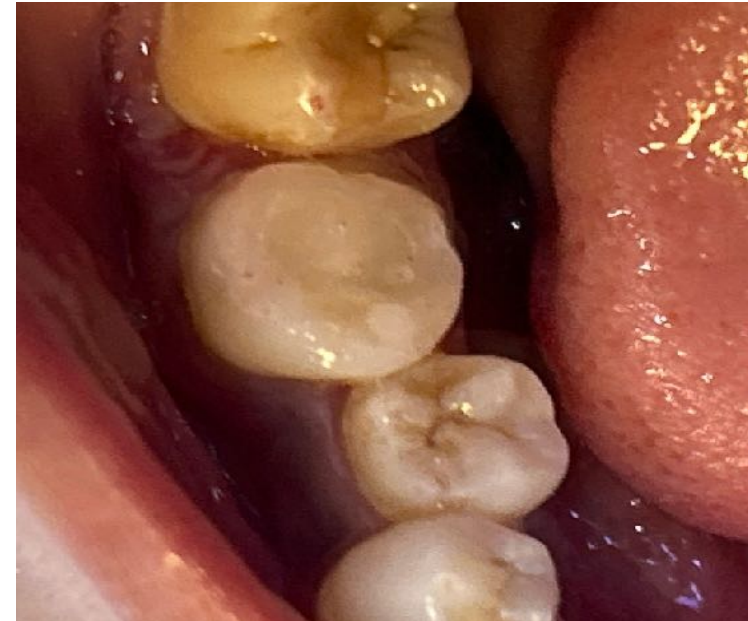2 fiber posts placed



X-ray showing 2 posts



Post endo-composite restoration  
done



Intra oral photograph showing composite  
restoration

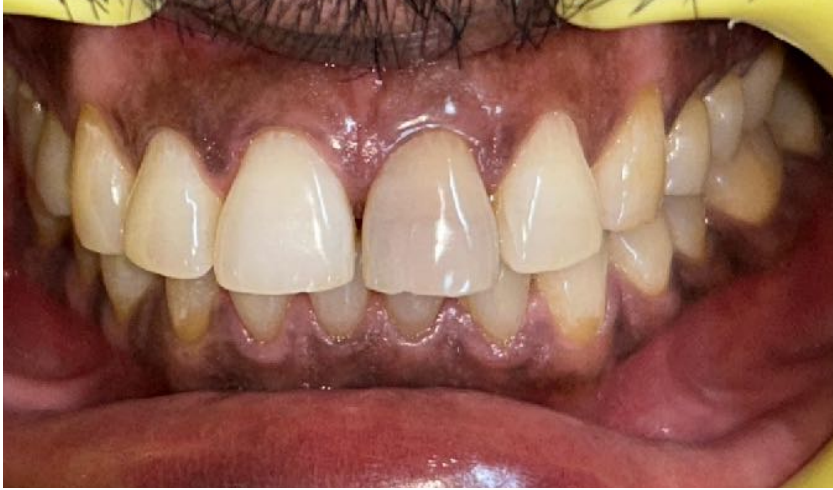

## CASE 8

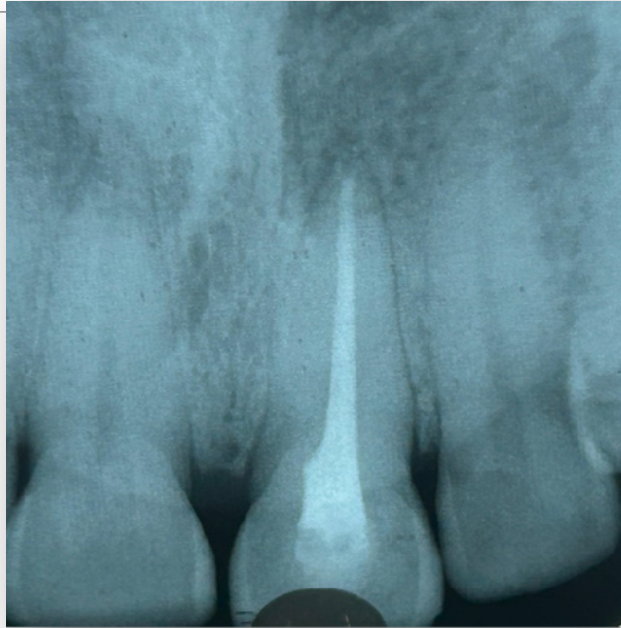
---

# NON-VITAL BLEACHING

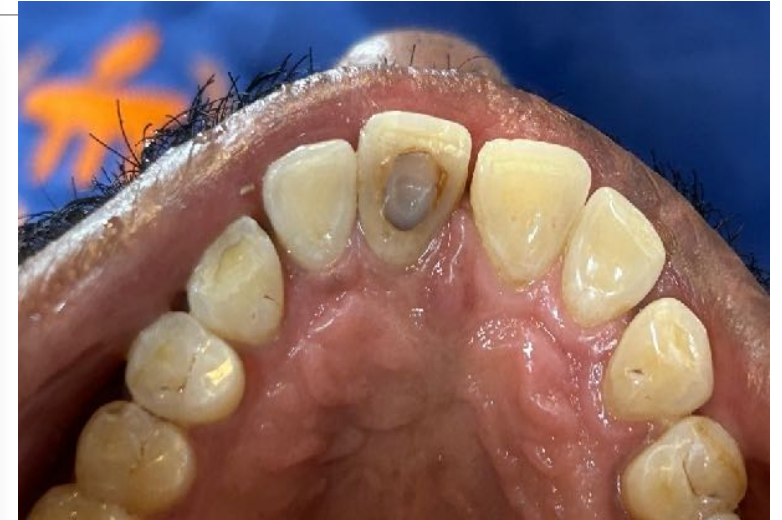- COMPLAINS OF- DISCOLORATION IN THE UPPER LEFT FRONT TOOTH REGION
- GENDER-MALE
- AGE-46
- TOOTH NUMBER-21



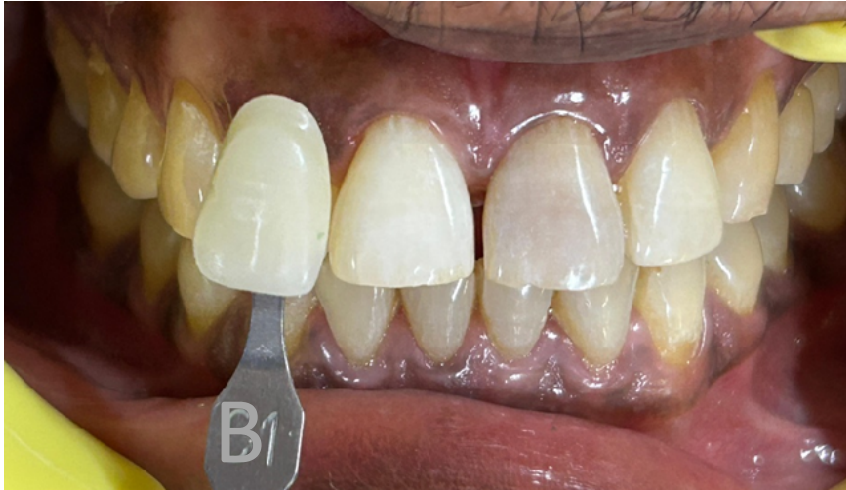Intra oral photograph showing  
tooth discoloration wrt 21



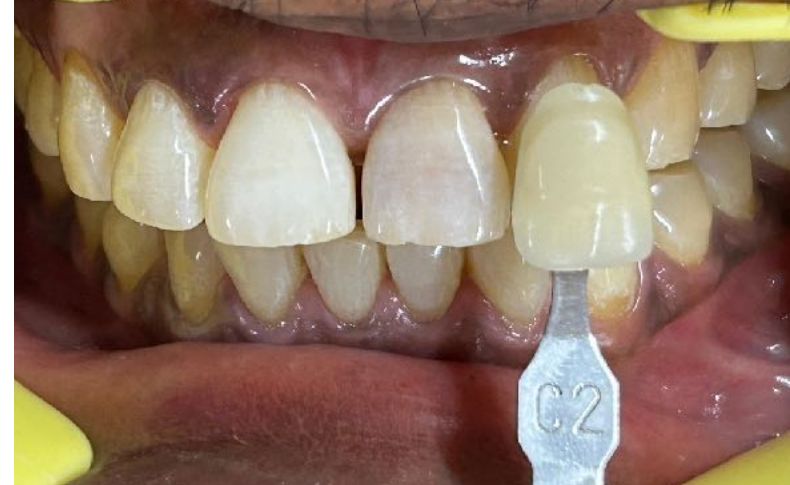Pre-operative radiograph  
showing obturation done  
wrt 21



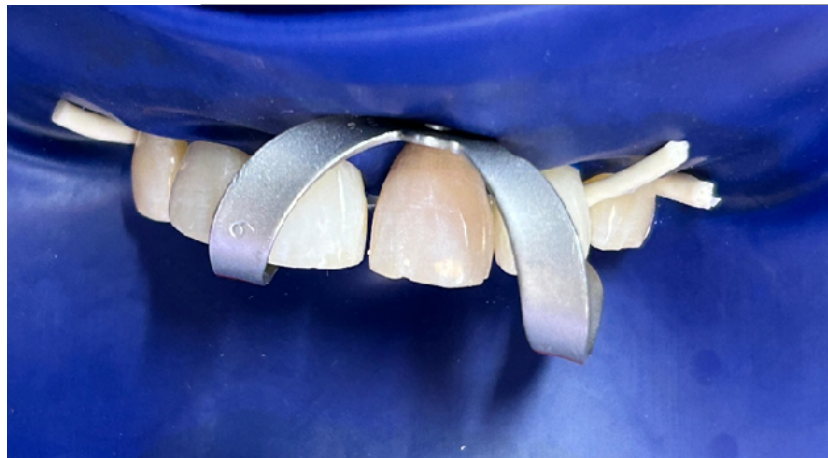Intra oral photograph



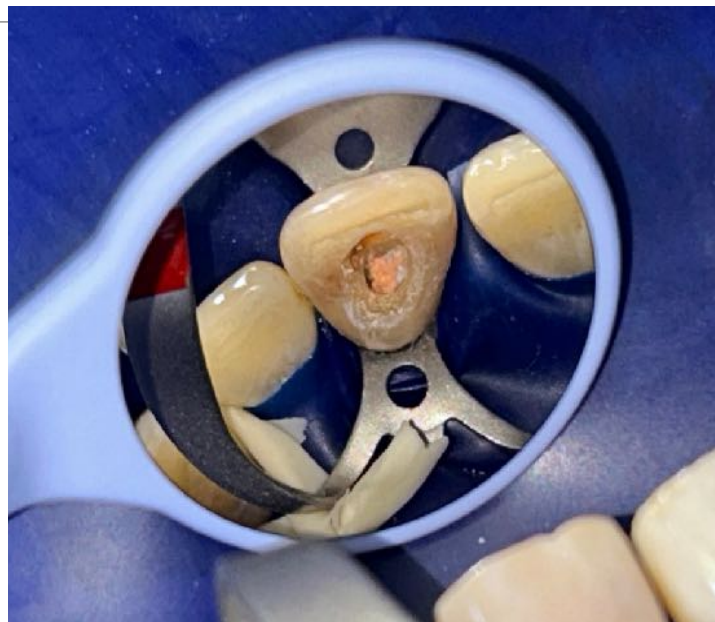11 with shade B1 (vita shade guide)



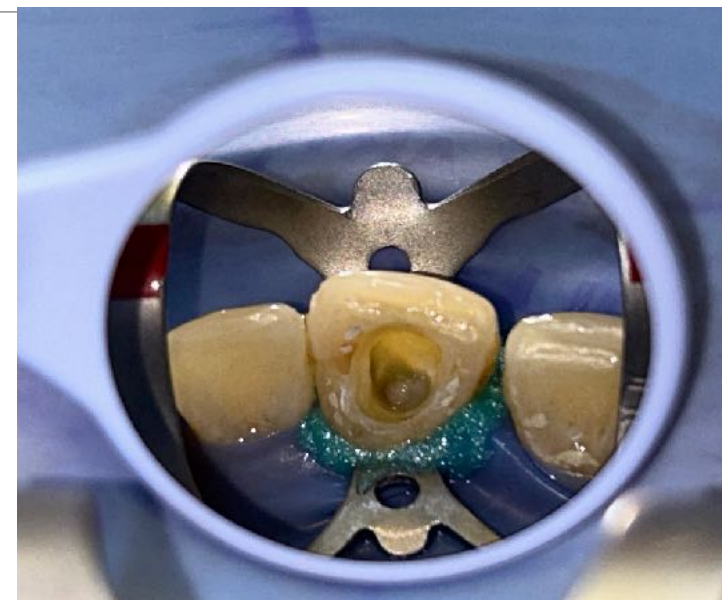
21 with shade C2



Under rubber dam isolation

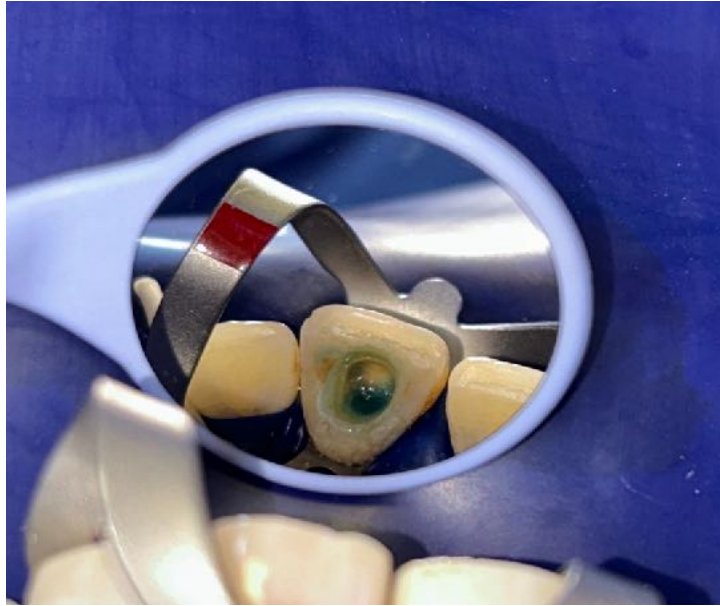


Permanent restoration removed

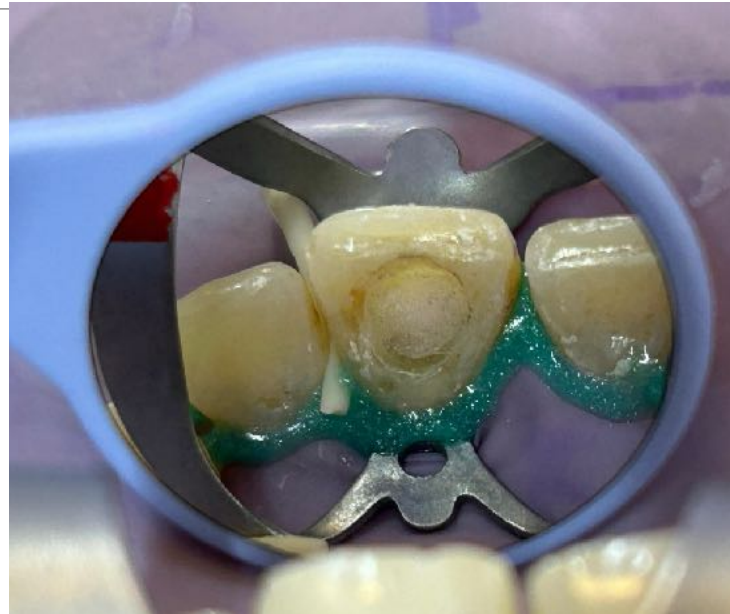

2mm gutta percha removed  
below the orifice level and GIC  
barrier placed

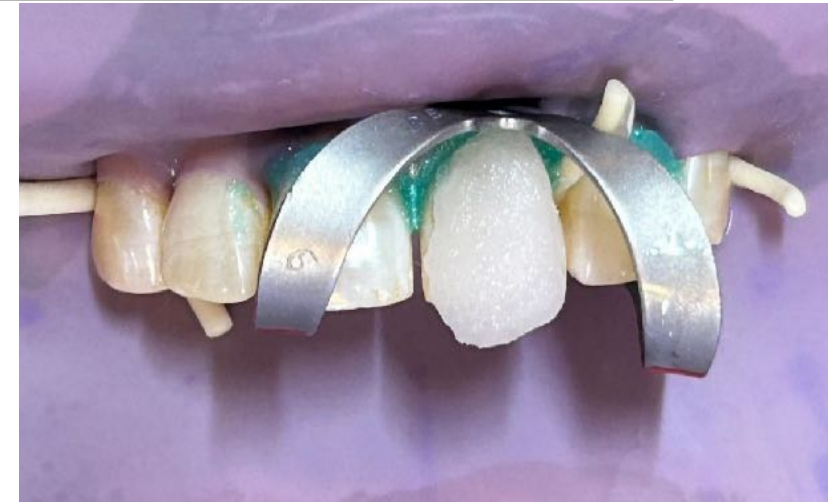



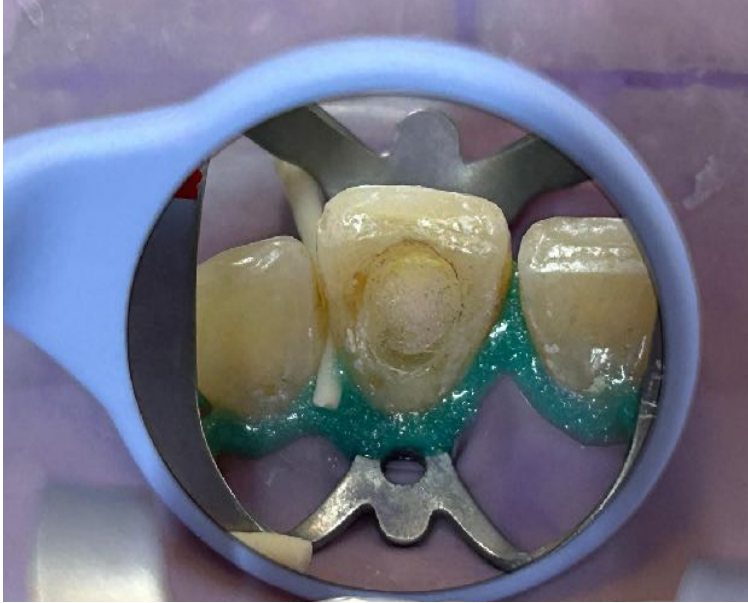Etchant applied to remove the debris and washed away



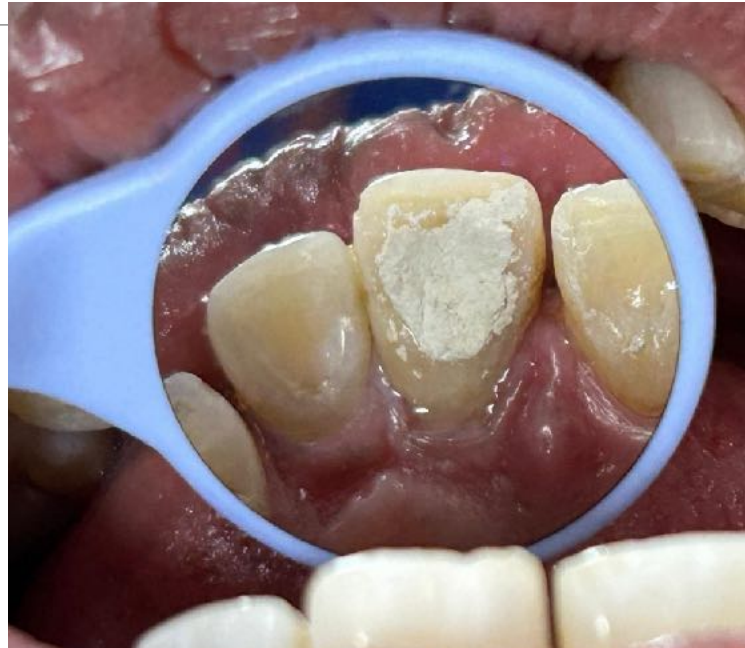H<sub>2</sub>O<sub>2</sub> dipped with cotton and placed in pulp chamber and heated ,repeat this for 20min



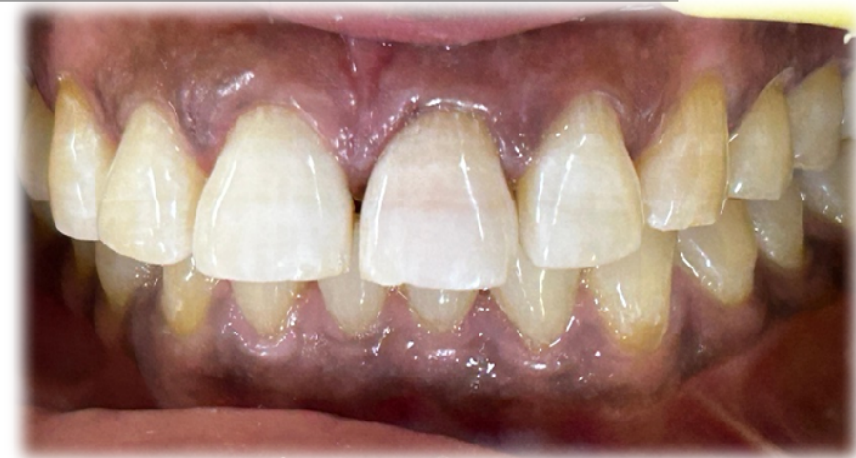H<sub>2</sub>O<sub>2</sub> cotton bed placed on labial surface and heated ,repeat this for 20 min



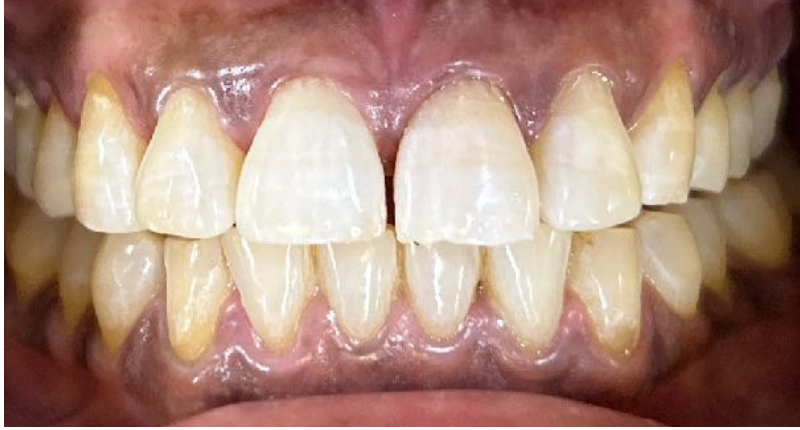Sodium perborate and H<sub>2</sub>O<sub>2</sub> paste placed in pulp chamber and cotton placed



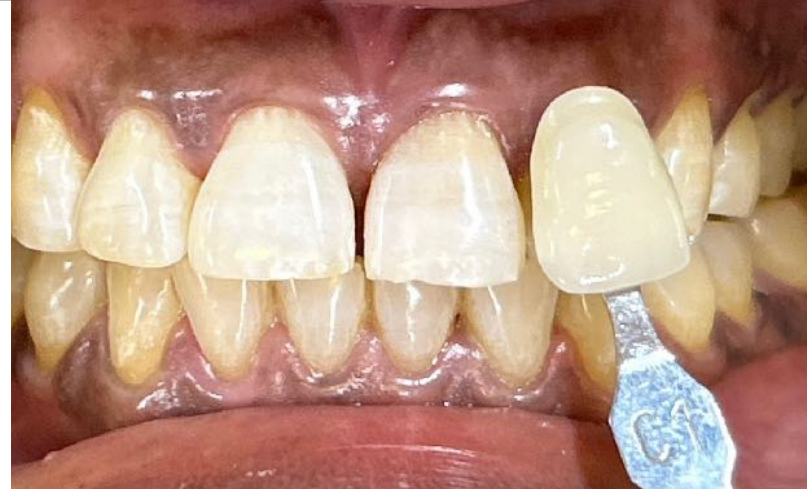Polycarboxylate cement placed



After first round of bleaching

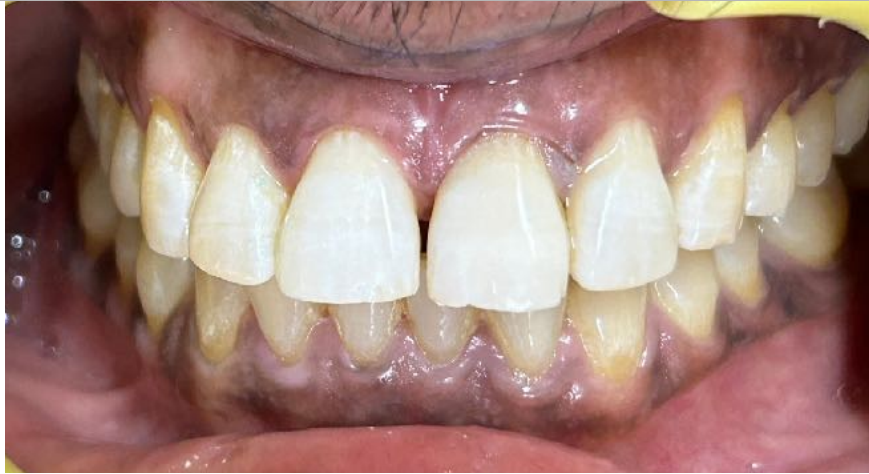

After second round of non vital bleaching

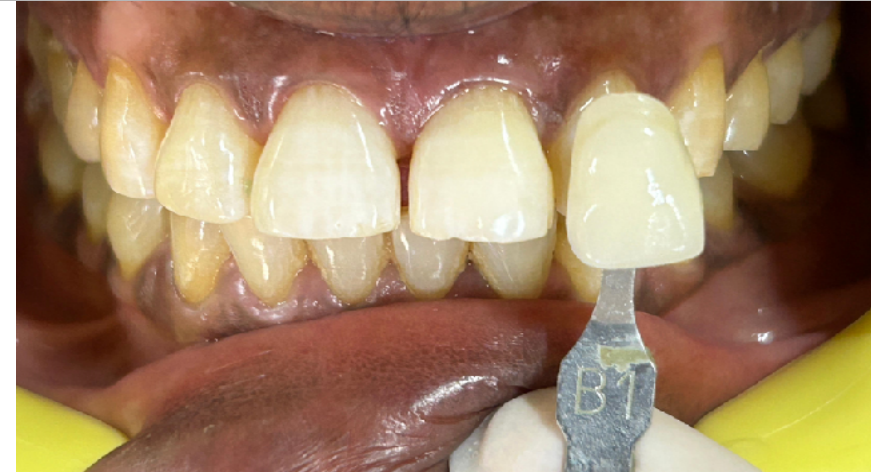

Shade has changed from C2 to C1





After third round of bleaching



Shade changed from C2 to B1



**THANK YOU!**